

Elements of Morphology: Standard Terminology for the Periorbital Region

Bryan D. Hall,^{1*} John M. Graham Jr.,² Suzanne B. Cassidy,³ and John M. Opitz⁴

¹Department of Pediatrics, University of Kentucky, Lexington, Kentucky

²Medical Genetics Institute, Cedars-Sinai Medical Center, David Geffen School of Medicine at UCLA, Los Angeles, California

³Division of Medical Genetics, Department of Pediatrics, University of California—San Francisco, San Francisco, California

⁴Departments of Pediatrics (Division of Medical Genetics), Pathology, Human Genetics, Obstetrics and Gynecology, University of Utah Health Sciences Center, Salt Lake City, Utah

Received 18 September 2008; Accepted 15 October 2008

An international group of clinicians working in the field of dysmorphology has initiated the standardization of terms used to describe human morphology. The goals are to standardize these terms and reach consensus regarding their definitions. In this way, we will increase the utility of descriptions of the human phenotype and facilitate reliable comparisons of findings among patients. Discussions with other workers in dysmorphology and related fields, such as developmental biology and molecular genetics, will become more precise. Here we introduce the anatomy of the periorbital area and define and illustrate the terms that describe the major characteristics of the periorbital area. © 2009 Wiley-Liss, Inc.

Key words: terminology; definitions; periorbital structures; eyebrows; eyelashes; eyelids; palpebrae; telecanthus; lacrimal glands

INTRODUCTION

General

This article is part of a series of six articles defining the morphology of regions of the human body [Allanson et al., in press-b; Biesecker et al., in press; Carey et al., in press; Hennekam et al., in press; Hunter et al., in press]. The series is accompanied by an introductory article describing general aspects of this project [Allanson et al., in press-a]. The reader is encouraged to consult the introduction when using the definitions.

Anatomy

The general anatomy of the non-globe periorbital region is depicted in Figure 1. The definitions for the terms utilized in describing the features within this region are listed alphabetically. The anatomy of the various structures is described in more detail below.

Brow: The soft tissue at the junction of the frontalis and orbicularis oculi muscles, overlying the bony supraorbital ridge.

Eyebrow: The arch of hair on the brow (Fig. 2) [Goss, 1959]. The eyebrows usually extend further laterally than medially, in relation to the eye, and are wider and thicker medially. Based on observed

How to Cite this Article:

Hall BD, Graham JM Jr., Cassidy SB, Opitz JM. 2009. Elements of morphology: Standard Terminology for the periorbital region.

Am J Med Genet Part A 149A:29–39.

localized abnormalities of the eyebrow, it is useful to divide the eyebrow into three parts: medial, middle (central), and lateral. The hairs of the medial part are oriented laterally, while those of the middle (central) part are oriented superolaterally. The transition between the middle and lateral parts is less frequently visible. Some syndromes have unique patterns of aberrations in one or more of these three areas. The eyebrow is sometimes referred to as the supercilium.

Eye spacing: There is wide variation in interorbital distance and in the placement of the canthi [Cohen et al., 1995]. A number of terms in this article address the nomenclature of these variations. Several of the terms are commonly confused (especially telecanthus and hypertelorism). Some of the variations are illustrated in Figure 3.

Eyelashes: Hairs that emanate from the margins of the eyelids [Goss, 1959].

Eyelid (syn. Blepharon, palpebra {plural: palpebrae}): A fold of skin and its subcutaneous components that covers the anterior globe. The upper lid is bounded by the soft tissue overlying the inferior border of the bony supraorbital ridge and inferiorly by the lid margin. The lower lid is bounded by the soft tissue overlying the infraorbital rim and superiorly by the lid margin. A

*Correspondence to:

Bryan D. Hall, Department of Pediatrics, Division of Clinical/Biochemical Genetics and Dysmorphology, Kentucky Clinic, University of Kentucky, Lexington, KY 40536-0284. E-mail: bdelhall@insightbb.com

Published online 5 January 2009 in Wiley InterScience (www.interscience.wiley.com)

DOI 10.1002/ajmg.a.32597

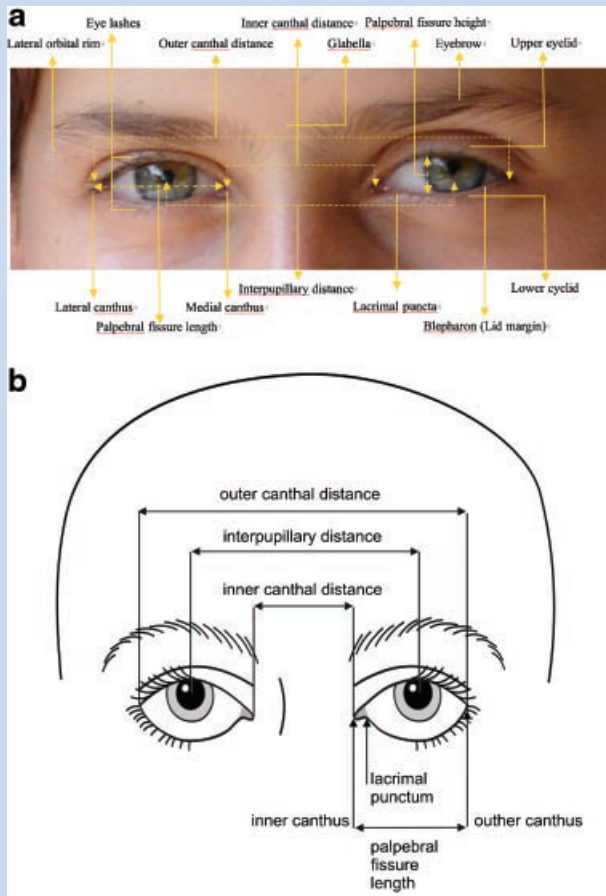


FIG. 1. Periocular anatomy and terminology. **A:** A periocular image with a number of landmarks indicated. **B:** A schematic diagram showing only the major periocular features that are commonly measured [courtesy R. Hennekam, M.D.].

crescent-shaped crease on the upper eyelid represents the location of attachment of the levator palpebrae muscle to the orbicularis oculi muscle [Goss, 1959].

Lacrimal punctum {plural: **puncta**}: This structure represents the external aperture of the tear duct system. It can be absent,

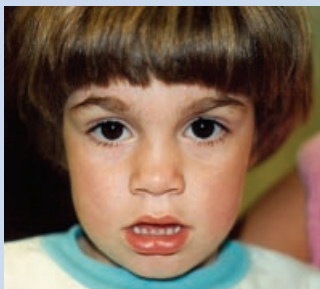

FIG. 2. Typical eyebrow with mild arch, widening medially, and gradual thinning laterally.

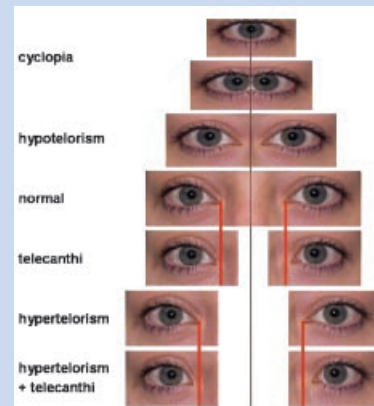


FIG. 3. Visual comparison of normal eye spacing and medial [inner] canthal position with *Closely spaced eyes*, *Widely spaced eyes* and *Telecanthus* [courtesy of R. Hennekam, M.D.]. These images were artificially manipulated to simulate clinically observed variations.

malpositioned, or obstructed [Ogawa and Gonnering, 1991], and several terms below address these findings.

Palpebral fissure: When the eye is open the palpebral fissure is a scaphoid space or outline formed by eyelid margins. The palpebral fissure extends from the lateral canthus (outer canthus) to the medial canthus (inner canthus). Many factors (e.g., size, slant, eyelid architecture, ptosis) can contribute to configuration of the palpebral fissures [Hall et al., 2007].

Note that the plurality of the terms is variable. The default chosen is to specify the singular form of the term unless the term relates to a pair of structures and only makes sense in the plural form (e.g., *Eyes*, *closely spaced*) or refers to a structure with many elements (e.g., *Eyelashes*, *sparse*). The plurality of the terms was ignored when they were alphabetized and the terms were grouped together (e.g., “Eye. . .” and “Eyes. . .” are grouped together, and not interrupted by “Eyelashes. . .”).

DEFINITIONS

Ablepharon

Definition: Absent eyelids (Fig. 4). *objective*

Comments: In *Ablepharon* the globe is continuously exposed [Stevens and Sargent, 2002]. It is arguable whether true aplasia of

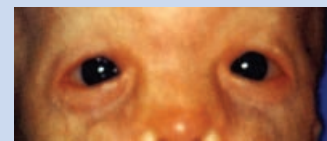

FIG. 4. *Ablepharon*, or absent eyelids, in a patient who also has *Telecanthus* and *Downslanted palpebral fissures* [courtesy of C. Stevens, M.D.].

the eyelids exists, or whether this represents severe hypoplasia. Nevertheless, as it is difficult or impossible to make this distinction on clinical grounds, the term was felt to be useful.

Synonym: Absent eyelids

Ankyloblepharon

Definition: Partial fusion of the upper and lower eyelid margins by single or multiple bands of tissue (Fig. 5). *objective*

Comment: This term derives from Weiss et al. [1992]. A minimally expressed form, especially when located fully laterally, may be more difficult to ascertain and would be a subjective feature. A band may break and leave no evidence of its presence. Note that this term is distinct from *Cryptophthalmos*.

Synonym: Eyelid synechia; Ankyloblepharon filiforme adnatum

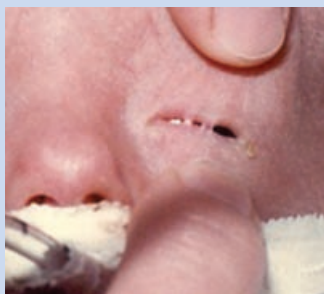

FIG. 5. *Ankyloblepharon*, or partial fusion of the eyelids, in a patient who also has *Short palpebral fissures*.

Ankyloblepharon filiforme adnatum: See *Ankyloblepharon*

Antimongoloid slant: See *Palpebral fissures, downslanted*

Atrichia: See *Eyelashes, sparse*

Blepharochalasis

Definition: Lax, wrinkled, and baggy eyelid skin (Fig. 6). *subjective*

Comment: This finding is usually more apparent in the upper eyelid. The eyelid tissue thickness is usually also reduced. The feature is frequent in older persons [Held and Schneiderman, 1990].

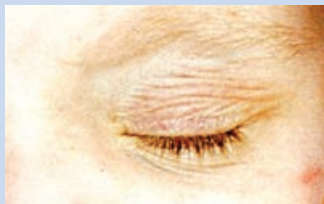

FIG. 6. *Blepharochalasis*, wrinkled, thin eyelids, which in this patient is limited to the upper lids.

Blepharophimosis

Definition: A fixed reduction in the vertical distance between the upper and lower eyelids with short palpebral fissures (Fig. 7). *subjective*

Comment: This term is derived from Cunniff et al. [1998]. It is an acknowledged bundled term. When palpebral fissures are severely shortened, they cannot be widely separated, actively or passively. *Ptosis* is the term to be used when the reduction in eyelid opening is not fixed but can be increased actively or passively. Blepharophimosis is often associated with *Epicanthus inversus*.

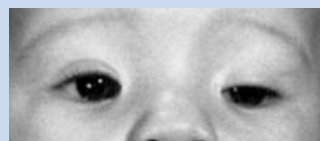

FIG. 7. *Blepharophimosis*, tight lids with short palpebral fissures giving a pseudoptosis. This patient also has *Epicanthus inversus*, which is often associated, but not required for the finding.

Blepharoptosis: See *Ptosis*

Ciliary trichomegaly: See *Eyebrows, long*

Cryptophthalmos

Definition: Absent palpebral fissures, with skin passing continuously from the forehead or eyebrow onto the cheek (Fig. 8). *subjective*

Comments: This term is based on Saal et al. [1992]. This is an acknowledged bundled term, though the separate coding of the components (palpebral fissure absence; presence of eyelashes) was deemed impractical. This is typically associated with a rudimentary or small globe. Frequently, a tuft of hair accompanies the aberrant skin

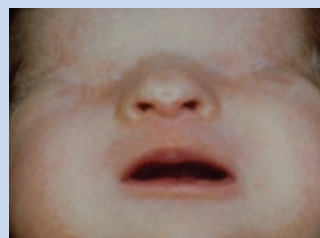


FIG. 8. *Cryptophthalmos* secondary to skin covering the lids and palpebral fissures [courtesy of John M. Graham, M.D.].

Dystopia canthorum: See *Telecanthus*

Ectropion

Definition: An outward turning (eversion) or rotation of the eyelid margin (Fig. 9). *subjective*

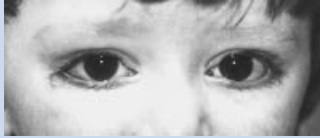

FIG. 9. *Ectropion of the lower lid, or outward turned (everted) lower eyelid margins. See also Figure 34.*

Comment: This term is derived from Cheng and Biglan [2002]. This finding is frequently associated with overexposure of the palpebral and scleral conjunctiva and cornea. It usually involves the lower eyelid. Modifiers such as “lower” and “lateral” may be applied as appropriate.

Entropion

Definition: An inward turning (inversion) of the eyelid margin (Fig. 10). *subjective*

Comment: The inward turned eyelid margin increases the potential for mechanical irritation of the eye by eyelashes [Cheng and Biglan, 2002]. This should be distinguished from *Epiblepharon*.

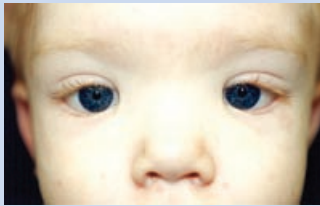

FIG. 10. *Entropion, or turned-in lower eyelids. This patient has congenital lymphedema, but this finding is not required for Entropion (Note that the illustration in Fig. 41 Upper eyelid fullness, is the maternal grandmother of the patient in this figure). The patient also has Telecanthus and Widely spaced eyes.*

Epiblepharon

Definition: Redundant eyelid skin pressing the eyelashes against the cornea and/or conjunctiva (Fig. 11). *subjective*

Comment: This term is based on Lemke and Stasior [1981]. This should be distinguished from *Entropion* (see above).

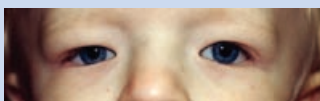

FIG. 11. *Epiblepharon in a young boy with folded-down upper eyelid skin, which is overlapping the palpebral aperture. He also has Downslanted palpebral fissures.*

Epicranial fold: See *Epicanthus*

Epicanthus

Definition: A fold of skin starting above the medial aspect of the upper eyelid and arching downward to cover, pass in front of and lateral to the medial canthus (Fig. 12A). *subjective*

Comment: In extreme cases, the skin fold can start as high as the eyebrow [Hall et al., 2007]. This is called epicanthus superciliaris (Fig. 12B).

Synonym: Epicranial fold; Epicanthus palpebralis

Epicanthus Inversus

Definition: A fold of skin starting at or just below the medial aspect of the lower lid and arching upward to cover, extend in front of and lateral to the medial canthus (Fig. 12C). *subjective*

Comment: For additional information on this finding, see [Oley and Baraitser, 1988].

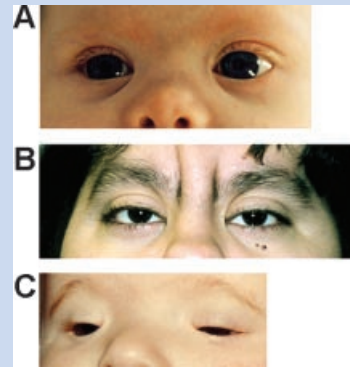


FIG. 12. A: *Epicanthus*, which comprises epicanthal folds coming from skin above the lid across and in front of medial canthi. B: *Epicanthus superciliaris*, which comprises more extensive epicanthal folds with their origins in the eyebrow. C: *Epicanthus inversus*, which is the reverse of epicanthal folds with its origin at or below the lower eyelid margin. See also Figure 7.

Eyes, Closely Spaced

Definition: Interpupillary distance more than 2 SD below the mean (Fig. 13). *objective* OR

Interpupillary distance below the 3rd centile. *objective* OR

The interpupillary distance appears to be decreased. *subjective*

Comment: The finding is measured according to Hall et al. [2007]. Note that the data from Hall et al. [2007] show SD for newborns and centiles for older patients. In the latter data, there is a continuing increase in this measurement between 14 and 15 years of age, so in the objective finding cannot be made using these norms in persons above 15 years of age. See Figure 3 for a gestalt of normal and abnormal eye spacing.

Synonym: Hypotelorism

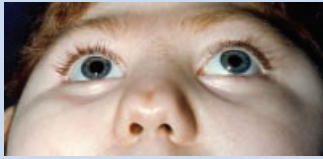

FIG. 13. *Closely spaced eyes, in a child. See also Figure 36.*

Eye, Deeply Set

Definition: An eye that is more deeply recessed into the plane of the face than is typical (Fig. 14). *subjective*

Comments: This finding should be distinguished from a prominent supraorbital ridge or inferior orbital margin. In *Deeply set eyes*, the globe is recessed in comparison to the overall prominence of the face. There is no known objective measurement, and diagnosing this feature depends heavily on the experience of the observer.

Synonym: Sunken eyes

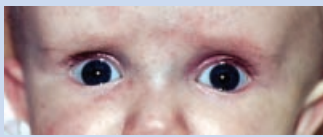

FIG. 14. *Deeply set eyes in a child.*

Eyes, Widely Spaced

Definition: Interpupillary distance more than 2 SD above the mean (newborns 27–41 weeks gestational age Fig. 15). *objective* OR

Interpupillary distance above the 97th centile (0–15 years of age). *objective* OR

The interpupillary distance appears to be increased. *subjective*

Comment: The finding is measured according to Hall et al. [2007]. Note that the data from Hall et al. [2007] show continuing increase in this measurement between 14 and 15 years of age, so this finding should only be made according to the subjective definition

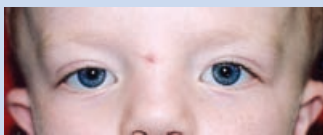

FIG. 15. A boy with *Widely spaced eyes, subjective* but without *Telecanthus*, demonstrating the independence of these two features. See also Figures 10, 30, 33, and 40B.

in persons above 15 years of age. It is important to distinguish between truly increased interpupillary distance and the apparently increased spacing that is caused by *Telecanthus* (see that entry for additional discussion). See Figure 3 for an illustration of variations of eye spacing.

Synonym: Hypertelorism

eyebrow, Broad

Definition: Regional increase in width of the eyebrow (Fig. 16). *subjective*

Comment: broadening or flaring can be medial or lateral, and the term may be modified by appending one of these words to the term (see Fig. 16). Flaring is used to describe a widening with a change in direction of the hairs constituting the eyebrow, but these terms are considered synonymous here.

Synonym: Flared eyebrow



FIG. 16. *Broad medial eyebrows in a boy. In this patient, the modifier of medial is inserted into the primary term.*

eyebrow, bushy: See *Eyebrows, thick*

eyebrow, Highly Arched

Definition: Increased height of the central portion of the eyebrow, forming a crescent, semicircular, or inverted U shape (Fig. 17). *subjective*

Comment: Most eyebrows have some arch with down turning medially and laterally. We know of no normative data for eyebrow arching. Identifying this feature is dependent on the experience of the observer. It may help to closely compare the shape/arching with that of siblings and parents.

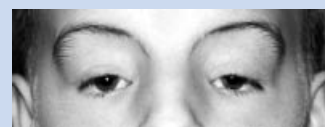

FIG. 17. *Highly arched eyebrows in a young man. In this patient, the eyebrows are high-set and thin and they ride above the supraorbital rim, although these features are not required for the term to be used.*

eyebrow, hirsutism of: See *eyebrow, thick*

eyebrow, Horizontal

Definition: An eyebrow that extends straight across the brow, without curve (Fig. 18). *subjective*

Comment: Evaluation should be performed with the face at rest. Horizontal eyebrows are an uncommon finding.

Synonym: Straight eyebrows

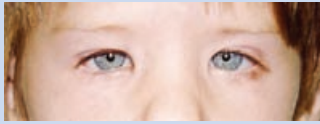

FIG. 18. *Horizontal eyebrows*, which extend straight across from medial to lateral in this girl. See also Figure 19.

Eyebrow, hypertrichosis of: See *Eyebrow, thick*

Eyebrow, Laterally Extended

Definition: An eyebrow that extends laterally beyond the orbital rim rather than turning gently downward at that location (Fig. 19). *subjective*

Comment: The degree of extension beyond the orbital rim considered abnormal has not been established. This feature is also uncommon.

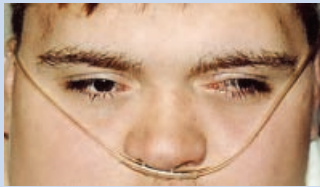


FIG. 19. *Laterally extended eyebrows* in a teenage boy whose eyebrows extend far beyond the lateral orbital wall. He also has *Horizontal eyebrows*, but this should be coded separately.

Eyebrow, Sparse

Definition: Decreased density/number and/or decreased diameter of eyebrow hairs (Fig. 20). *subjective*

Comment: Sparseness can be regional (medial, central, lateral) or total. These modifiers should be incorporated into the term, when appropriate.

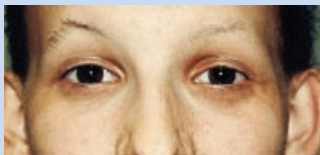


FIG. 20. *Sparse eyebrows* in a girl with other features of ectodermal dysplasia. See also Figure 25.

Synonym: Hypotrichosis of the eyebrow.

Eyebrow, straight: See *Eyebrow, horizontal*

Eyebrow, Thick

Definition: Increased density/number and/or increased diameter of eyebrow hairs (Fig. 21). *subjective*

Comment: Thickness can be regional (medial, middle (central), lateral) or total. These modifiers should be incorporated into the term, when appropriate.

Synonym: Hypertrichosis of the eyebrow; Bushy eyebrow

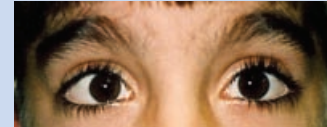

FIG. 21. *Thick eyebrows*, in a patient who also has *Prominent eyelashes* as well. This pre-teenage boy also shaves his facial hair.

Eyelashes, Absent

Definition: No eyelashes are present (Fig. 22). *objective*

Comment: This term is based on Ahmad et al. [1998]. Often this finding is congenital and associated with alopecia universalis, but this should be coded separately.

Synonym: Atrichia of eyelashes

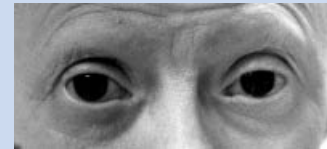

FIG. 22. *Absent eyelashes* or atrichia or in an adult female.

Eyelashes, Long

Definition: Mid upper eyelash length >10 mm (Fig. 23). *objective*
OR

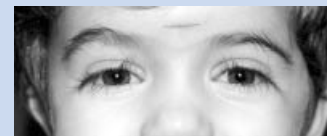

FIG. 23. *Long eyelashes*, in a boy. Note that, in addition to their length, the eyelashes are unusually angled, although that feature is not required for the finding of *Long eyelashes*. See also Figure 24.

Increased length of the eyelashes. *subjective*

Comment: Measurement should be done on the longest lashes, which are usually at the center of the lid. Normal values are 7.99 ± 1.05 mm in boys and 7.76 ± 1.03 mm in girls [Pucci et al., 2005].

Synonym: Ciliary trichomegaly.

Eyelashes, Prominent

Definition: Eyelashes that draw the attention of the viewer due to increased density and/or length and/or curl without meeting the criteria of trichomegaly (Fig. 24). *subjective*

Comment: This is admittedly a bundled term, but it may be useful in clinical practice.

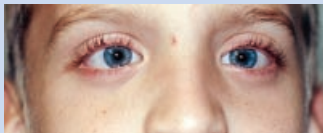

FIG. 24. *Prominent eyelashes* in a boy. He also has the finding of *Long eyelashes*, but that should be coded separately. See also Figure 21.

Eyelashes, Sparse

Definition: Decreased density/number of eyelashes (Fig. 25). *subjective*

Comment: Sometimes *Sparse eyelashes* are abnormally formed eyelashes. The sparseness may be limited to one portion of the eyelid. We know of no normative data for *Sparse eyelashes*.

Synonym: Hypotrichosis of eyelashes

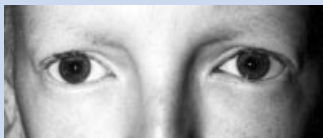

FIG. 25. *Sparse eyelashes* in a girl who also has some thinning of the lashes as well as *Sparse eyebrows* and *sparse scalp hair*. See also Figure 26.

Eyelid, Cleft

Definition: A short discontinuity of the margin of the lower or upper eyelid (Fig. 26). *subjective*

Comment: The lateral segment of the lower eyelid is most commonly involved. As the milder forms of this finding are clearly subjective and no boundary of subjective and objective is defined, the term is considered subjective. The term “eyelid coloboma” has been replaced because the word “coloboma” should be used only for defects at the site of fusion of embryologic structures, which is not the case here. Modifiers to designate the location of the cleft may be added, such as “lower” and “lateral.”

Synonym: Notched eyelid

Replaces: Eyelid coloboma

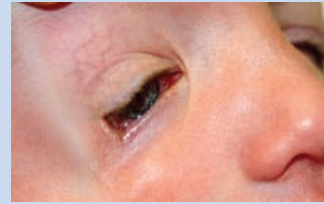

FIG. 26. *Cleft lower, outer eyelid* in a child. Note that the modifiers of “lower” and “outer” are added to the term. Note that she also has *Sparse lower eyelashes*.

Eyelid, coloboma of: See *Eyelid, cleft*

Eyelid, notched: See *Eyelid, cleft*

Hypertelorism: See *Eyes, widely spaced*

Hypotelorism: See *Eyes, closely spaced*

Hypotrichosis: See *Eyebrows, sparse* or *Eyelashes, sparse*

Infra-Orbital Crease

Definition: Skin crease extending from below the inner canthus laterally along the malar process of the maxilla and zygoma (Fig. 27). *subjective*

Comment: This feature is often found in the presence of hypoplasia of the malar process of the maxilla or zygoma, but this should be described separately. See *Infra-orbital fold* for a related term.




FIG. 27. *Infra-orbital creases* in a girl who also has *Infraorbital folds*, *flat malar bones*, and *laterally protruding ears*. See also Figure 33.

Infra-Orbital Fold

Definition: Elevated ridge(s) of skin starting well below the medial aspect of the lower lid that curves gradually upward toward and/or across the nasal bridge (Fig. 28). *subjective*

Comments: This excludes *Epicanthus inversus*. See *Infra-orbital crease* for a related term.

Lacrimal Punctum, Absence

Definition: No identifiable superior and/or inferior lacrimal punctum (Fig. 29). *objective*

Comments: The openings of the tear ducts are normally located at the medial margin of each eyelid. The opening on the lower eyelid

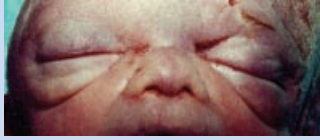

FIG. 28. *Infra-orbital folds* associated with upper facial edema (the latter is not required for the finding to be made). Note that these folds are oriented toward the lateral borders of the nasal bridge. See also Figure 27.

border is more visible than the opening on the upper eyelid border. Absence of the lacrimal punctum is uncommon [Ferreira et al., 2000] and although it is typically presumed to be caused by agenesis, we avoid causal mechanisms in this terminology. There was some disagreement as to whether Nasolacrimal duct obstruction should be included in this terminology. As that assessment is primarily functional and not anatomic, it was removed.

Replaces: Agenesis of the lacrimal punctum

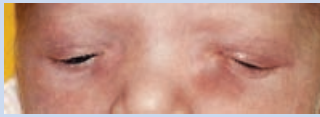

FIG. 29. This child has *Absence of the lacrimal puncta*. Note that she also has *Short palpebral fissures*, *Downslanted palpebral fissures*, *Telecanthus*, and *Nasolacrimal duct obstruction* with erythematous and swollen lacrimal ducts below the medial canthi.

Lacrimal Punctum, Ectopic

Definition: Positioning of a lacrimal punctum other than at the medial margins of the eyelid (Fig. 30). *subjective*

Comment: The openings of the tear ducts are normally located at the medial margin of each eyelid. The opening on the lower eyelid border is more visible than the opening on the upper eyelid border. Ectopic positions can include the upper eyelid, nasal bridge, or inferior to medial aspect of the lower lid.

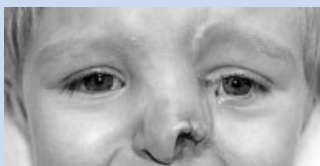

FIG. 30. The left eye shows an inferiorly placed medial canthus and *Ectopic lacrimal punctum* plus a defect in the left nostril.

Lagophthalmos

Definition: Inability to totally close the eyelids while awake, asleep, or both (Fig. 31). *subjective*

Comment: It may be an isolated finding or part of a syndrome [Korula et al., 1995] and can be associated with *Ectropion*. *Lagophthalmos* frequently results in chronic conjunctival and/or corneal irritation.

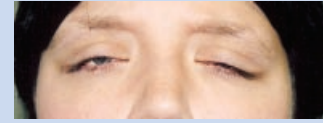


FIG. 31. This teenage girl has *Lagophthalmos*, which has caused her to have severe corneal and scleral irritation.

Mongoloid slant: See *Palpebral fissure, upslanted*

Palpebral Fissure, Almond-Shaped

Definition: A shape created by an acute downward arching of the upper eyelid and upward arching of the lower eyelid, toward the medial canthus, which gives the outline of the palpebral fissures the configuration of an almond; thus, the maximum distance between the fissures is offset from, and medial to, the center point (Fig. 32). *subjective*

Comments: The almond configuration tends to dissipate with time as the surrounding tissues (e.g., eyelid, nasal bridge) grow.

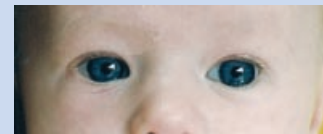

FIG. 32. This shows a typical *Almond-shaped palpebral fissure* of the left eye. A comparison with the right eye illustrates the difference, that being the sharp descent of the upper medial canthal fold.

Palpebral Fissure, Downslanted

Definition: The palpebral fissure inclination is more than 2 SD below the mean for age (Fig. 33). *objective* OR

The inclination of the palpebral fissure is less than typical for age. *subjective*

Comments: The slant, or inclination, of the palpebral fissure is defined as the angle formed by two lines: an imaginary line that connects the lateral canthus and the medial canthus of each eye, and an imaginary horizontal line formed by the two medial canthi when the patient holds their head with the facial midline vertical, the head in a neutral vertical position (neither flexed nor extended) and the gaze forward [Farkas, 1994]. Palpebral fissure inclination norms are

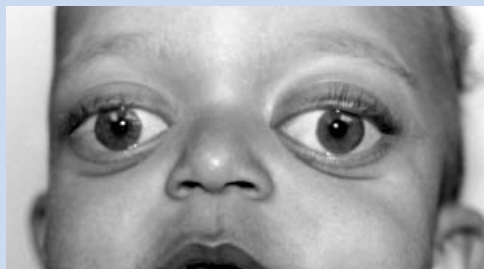

FIG. 33. This boy has *Downslanted palpebral fissures, Widely spaced eyes, Proptosis, and Infra-orbital creases.* See also Figures 4, 11, 29, 38, and 39.

specified in Farkas [1994] for Caucasians (pg. 283) and for Chinese and African-American populations (limited data, pgs 342, and 349, respectively). Hall et al. [2007] only specifies norms for Caucasians between 6 and 16 years of age. Note that the mean inclination is slightly upslanting at all ages [Farkas, 1994; Hall et al., 2007]. Some features (e.g., *Ptosis* or *Epicanthus*) may hinder palpebral fissure inclination assessment. Malar and/or zygomatic hypoplasia and *Widely spaced eyes* may be associated with a downward slant.

Replaces: Antimongoloid slant

Palpebral Fissure, Long

Definition: Distance between the medial and lateral canthi is more than 2 SD above the mean for age (Fig. 34). *objective* OR

Apparently increased length of the palpebral fissures. *subjective*

Comment: Measurement techniques and norms are as specified in Hall et al. [2007] and Farkas [1994]. The term “wide palpebral fissure” is discouraged because this term is vague with respect to which dimension (vertical vs. horizontal) it refers to, coupled with the popular definition of “wide-eyed,” which refers to palpebral fissure height.

Replaces: Wide palpebral fissure

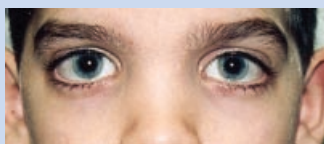

FIG. 34. Long palpebral fissures, and Lateral ectropion are obvious in this boy.

Palpebral Fissure, Short

Definition: Distance between the medial and lateral canthi is more than 2 SD below the mean for age (Fig. 35). *objective* OR

Apparently reduced length of the palpebral fissures. *subjective*

Comments: Measurement techniques and norms are as specified in Hall et al. [2007] and Farkas [1994]. These sources include more

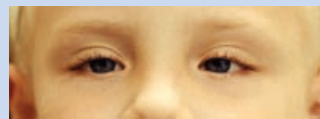

FIG. 35. Young female with mildly to moderately *Short palpebral fissures.* Note some mild *Ptosis.* See also Figures 5 and 29.

complete data for Caucasians than for other groups. Decreased palpebral fissure length may be accompanied by a decreased vertical distance between the upper and lower eyelid, which gives the eyes a more slit-like appearance and may give the appearance of *Ptosis*, but this should be coded separately if it is present. Severe shortening of the palpebral fissures leads to *Blepharophimosis*.

Palpebral Fissure, Upslanted

Definition: The palpebral fissure inclination is more than 2 SD above the mean for age (Fig. 36). *objective* OR

The inclination of the palpebral fissure is greater than typical for age. *subjective*

Comments: The slant, or inclination, of the palpebral fissure is defined as the angle formed by two lines: an imaginary line that connects the lateral canthus and the medial canthus of each eye, and an imaginary horizontal line formed by the two medial canthi when the patient holds their head with the facial midline vertical, the head in a neutral vertical position (neither flexed nor extended) and the gaze forward [Farkas, 1994]. Palpebral fissure inclination norms are specified in Farkas [1994] for Caucasians (pg. 283) and for Chinese and African-American populations (limited data, pgs 342, and 349, respectively). Hall et al. [2007] only specifies norms for Caucasians between 6 and 16 years of age. Upslanted palpebral fissures may be associated with microcephaly, but this should be coded separately. Some features (e.g., *Ptosis* or *Epicanthus*) may hinder palpebral fissure inclination assessment.

Replaces: Mongoloid slant

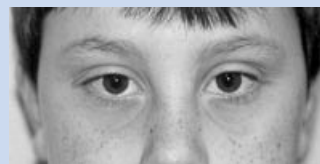

FIG. 36. Upslanted palpebral fissures, in a boy who also has *Closely spaced eyes.* See also Figure 41B.

Palpebral fissure, wide. See: *Palpebral fissure, long*

Proptosis

Definition: An eye that is protruding anterior to the plane of the face to a greater extent than is typical (Fig. 37). *subjective*

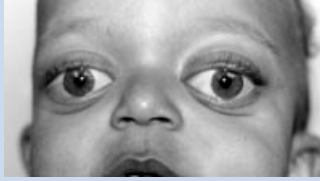

FIG. 37. Bilateral *Proptosis*. This is a duplicate of Figure 33.

Comments: This finding should be distinguished from underdevelopment of the supraorbital ridge or maxilla/zygoma. In *Proptosis*, the globe is anteriorly protuberant in comparison to the overall plane of the face. There is no known objective measurement, and diagnosing this feature depends heavily on the experience of the observer.

Synonym: Prominent eyes

Ptosis

Definition: The upper eyelid margin is positioned 3 mm or more lower than usual and covers the superior portion of the iris (Fig. 38). *objective* OR

The upper lid margin obscures at least part of the pupil. *subjective*

Comment: True ptosis usually occurs in the presence of normal palpebral fissure length. Apparent ptosis is seen in *Blepharophimosis* and other causes of *Short palpebral fissures*. Pseudoptosis occurs in the presence of severe zygomatic underdevelopment when the resulting dramatic downward eye slant pulls the upper eyelid diagonally across the globe.

Synonym: Blepharoptosis

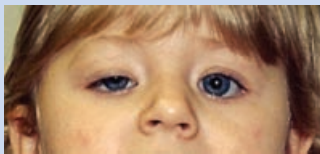


FIG. 38. *Ptosis* of the right eyelid. Note that the upper lid margin partially covers the right pupil (compare with normal left upper eyelid). She also has *Downslanted palpebral fissures*. See also Figure 35.

Synechiae: See *Ankyloblepharon*

Synophrys

Definition: Meeting of the medial eyebrows in the midline (Fig. 39). *subjective*

Comment: Cosmetic hair removal or shaving may obscure this feature. It is controversial whether the medial eyebrows must meet

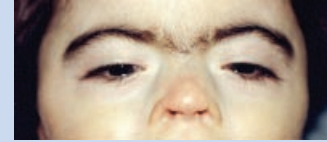

FIG. 39. A patient with *Synophrys* and *Downslanted palpebral fissures*.

in the midline to warrant this descriptor, as opposed to eyebrows that extend markedly toward the midline but do not meet.

Replaces: Unibrow

Telecanthus

Definition: Distance between the inner canthi more than 2 SD above the mean (Fig. 40). *objective* OR

Apparently increased distance between the inner canthi. *subjective*

Comments: *Telecanthus* may be present without (Fig. 40A) or with (Fig. 40B) *Widely spaced eyes*. In the latter case, *Widely spaced eyes* should be coded separately. Inner canthal distance varies among ethnic groups. Norms are available for American Africans [Murphy and Laskin, 1990], Chinese [Wu et al., 2000], and Caucasians [Laestadius et al., 1969; Feingold and Bossert, 1974; Merlob et al., 1984; Evereklioglu et al., 2001]. In the presence of an *Epicanthal fold*, ascertainment of inner canthal distance can be difficult.

Synonym: *Dystopia canthorum*

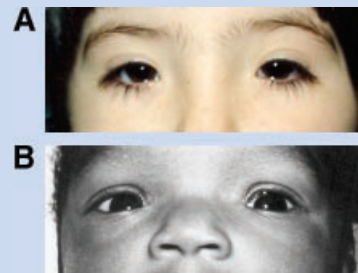

FIG. 40. A: *Telecanthus* with normal interpupillary distance. Note lack of adequate visualization of the sclera toward the medial canthi. B: *Telecanthus* with *Widely spaced eyes*. See also Figures 4, 10, 15, and 29.

Unibrow: See *Synophrys*

Upper Eyelid, Fullness of

Definition: Swelling or distention of the upper eyelid (Fig. 41). *subjective*

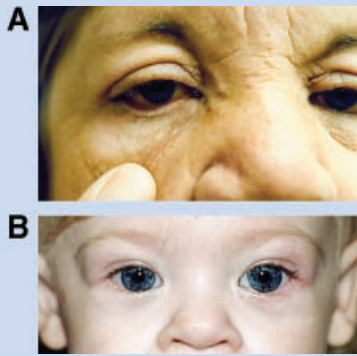


FIG. 41. A: Adult female with Upper eyelid fullness. In this case, the patient had eyelid edema which gives it fullness and which can invert the lids causing eye irritation. B: Localized Upper lateral eyelid fullness in a child who also has Upslanted palpebral fissures and stellate irides.

Comment: The swelling can be due to edema, fat or other depositions or inflammation. It is controversial whether there should be a separate term for fullness of the lateral upper eyelid.

REFERENCES

- Ahmad W, Irvine AD, Lam H, Buckley C, Bingham EA, Panteleyev AA, Ahmad M, McGrath JA, Christiano AM. 1998. A missense mutation in the zinc-finger domain of the human hairless gene underlies congenital atrichia in a family of Irish travellers. *Am J Hum Genet* 63:984–991.
- Allanson JE, Biesecker LG, Carey JC, Hennekam RCM. 2009a. Elements of morphology: Introduction. *Am J Med Genet Part A* 149A:2–5.
- Allanson JE, Cunniff C, Hoyme HE, McGaughan J, Muenke M, Neri G. 2009b. Elements of morphology: Standard terminology for the head and face. *Am J Med Genet Part A* 149A:6–28.
- Biesecker LG, Aase JM, Clericuzio C, Gurrieri F, Temple IK, Toriello H. 2009. Elements of morphology: Standard terminology for the hands and feet. *Am J Med Genet Part A* 149A:93–127.
- Carey JC, Cohen MM Jr, Curry CJR, Devriendt K, Holmes LB, Verloes A. 2009. Elements of morphology: Standard terminology for the lips, mouth, and oral region. *Am J Med Genet Part A* 149A:77–92.
- Cheng KP, Biglan AW. 2002. Ophthalmology Ch19 649–692. In *Atlas of pediatric physical diagnosis*. Zitelli BJ and Davis HW, Editors. 4th Ed. Mosby, St. Louis.
- Cohen MM, Richieri-Costa A, Guion-Almeida ML, Saavedra D. 1995. Hypertelorism: Interorbital growth, measurements, and pathogenetic considerations. *Int J Oral Maxillofac Surg* 24:387–395.
- Cunniff C, Curtis M, Hased SJ, Hoyme HE. 1998. Blepharophimosis: A causally heterogeneous malformation frequently associated with developmental disabilities. *Am J Med Genet* 75:52–54.
- Evereklioglu C, Yakinci C, Er H, Doganay S, Durmaz Y. 2001. Normative values of craniofacial measurements in idiopathic benign macrocephalic children. *Cleft Palate Craniofac J* 38:260–263.
- Farkas LG. 1994. *Anthropometry of the head and face*. New York: Raven Press. p 405.
- Feingold M, Bossert WH. 1974. Normal values for selected physical parameters: An aid to syndrome delineation. *Birth Defects Orig Artic Ser* 10:1–15.
- Ferreira APS, Gomez RS, Castro WH, Calixto NS, Silva RAP, Aguiar JB. 2000. Congenital absence of lacrimal puncta and salivary glands: Report of a Brazilian family and review. *Am J Med Genet* 94:32–34.
- Goss CM. 1959. In: Goss CM, editor. *Gray's Anatomy*. 27th edition. Philadelphia: Lea and Febiger Press. p 1118.
- Hall J, Allanson JE, Gripp K, Slavotinek A. 2007. *Handbook of normal physical measurements*. Oxford Medical Publishers, pp 132–139.
- Held JL, Schneiderman P. 1990. A review of blepharochalasis and other causes of the lax, wrinkled eyelid. *Cutis* 45:91–94.
- Hennekam RCM, Cormier-Daire V, Hall J, Mehes K, Patton M, Stevenson R. 2009. Elements of morphology: Standard terminology for the nose and philtrum. *Am J Med Genet Part A* 149A:61–76.
- Hunter A, Frias J, Gillessen-Kaesbach G, Hughes H, Jones K, Wilson L. 2009. Elements of morphology: Standard terminology for the ear. *Am J Med Genet Part A* 149A:40–60.
- Korula S, Wilson L, Salomonson J. 1995. Distinct craniofacial syndrome of lagophthalmia and bilateral cleft lip and palate. *Am J Med Genet* 59:229–233.
- Laestadius ND, Aase JM, Smith DW. 1969. Normal inner canthal and outer orbital dimensions. *J Pediatr* 74:465–468.
- Lemke BN, Stasiar OG. 1981. Epiblepharon: An important and often missed diagnosis. *Clin Pediatr* 20:661–662.
- Melrob P, Sivan Y, Reisner SH. 1984. Anthropometric measurements of the newborn infant 27–41 gestational weeks. *Birth Defects Orig Artic Ser* 20:1–52.
- Murphy WK, Laskin DM. 1990. Intercanthal and interpupillary distance in the Black population. *Oral Surg Oral Med Oral Pathol* 69:676–680.
- Ogawa GSH, Gonnering RS. 1991. Congenital nasolacrimal duct obstruction. *J Pediatr* 119:12–17.
- Oley C, Baraitser M. 1988. Blepharophimosis, ptosis epicanthus inversus syndrome (BPES syndrome). *J Med Genet* 25:47–51.
- Pucci N, Novembre E, Lombardi E, Massai C, Bernardine R, Caputo R, Campa L, Libero C, Vieruci A. 2005. Long eyelashes in a case series of 93 children with vernal keratoconjunctivitis. *Pediatrics* 115:86–91.
- Saal HM, Traboulsi EI, Gavaris P, Samango-Sprouse CA, Parks M. 1992. Dominant syndrome with isolated cryptophthalmos and ocular anomalies. *Am J Med Genet* 43:785–788.
- Stevens CA, Sargent LA. 2002. Ablepharon-macrostomia syndrome. *Am J Med Genet* 107:30–37.
- Weiss AH, Riscile G, Kouseff BG. 1992. Ankyloblepharon filiforme adnatum. *Am J Med Genet* 42:369–373.
- Wu KH, Tsai FJ, Li TC, Tsai CH, Peng CT, Wang TR. 2000. Normal values of inner canthal distance, interpupillary distance and palpebral fissure length in normal Chinese children in Taiwan. *Acta Paediatr Taiwan* 41:22–27.