

Elements of Morphology: Standard Terminology for the Lips, Mouth, and Oral Region

John C. Carey,^{1*} M. Michael Cohen Jr.,² Cynthia J.R. Curry,³ Koenraad Devriendt,⁴ Lewis B. Holmes,⁵ and Alain Verloes⁶

¹Division of Medical Genetics, Department of Pediatrics, University of Utah Health Sciences Center, Salt Lake City, Utah

²Department of Pediatrics, Dalhousie University, Halifax, Nova Scotia, Canada

³Genetic Medicine, Central California, Fresno, California

⁴Clinical Genetics, University of Leuven, Leuven, Belgium

⁵Department of Pediatrics, Harvard Medical School, Boston, Massachusetts

⁶Clinical Genetics Unit, Robert Debre Hospital, Paris, France

Received 13 October 2008; Accepted 16 October 2008

An international group of clinicians and scientists working in the field of dysmorphology has initiated the standardization of terms used to describe human morphology. The goals are to standardize these terms and reach consensus regarding their definitions. In this way, we will increase the utility of descriptions of the human phenotype and facilitate reliable comparisons of findings among patients. Discussions with other workers in dysmorphology and related fields, such as developmental biology and molecular genetics, will become more precise. Here we summarize the anatomy of the oral region and define and illustrate the terms that describe the major characteristics of the lips and mouth.

© 2009 Wiley-Liss, Inc.

Key words: nomenclature; definitions; terminology; lips; mouth; anatomy; anthropometry

INTRODUCTION

This paper is part of a series of six articles defining the morphology of regions of the human body [Biesecker et al., 2009; Hall et al., 2009; Hennekam et al., 2009; Hunter et al., 2009; Allanson et al., 2009b]. The series is accompanied by an introductory article describing the general aspects of this study and the principles used in establishing the definitions [Allanson et al., 2009a]. The reader is encouraged to consult the Introduction when using the definitions.

ANATOMY OF THE LIPS, MOUTH, AND ORAL REGION

General

The appearance of the lips varies with facial movement. Smiling and crying can alter dramatically the shape of the upper lip, as do

How to Cite this Article:

Carey JC, Cohen MM Jr., Curry CJR, Devriendt K, Holmes LB, Verloes A. 2009. Elements of morphology: Standard terminology for the lips, mouth, and oral region.

Am J Med Genet Part A 149A:77–92.

pursing or pouting. Therefore, the lips must be assessed when the subject has a relaxed (neutral) face: the eyes are open, the lips make gentle contact, and the teeth are slightly separated. The neck, jaw, and facial muscles should not be stretched nor contracted, and the face should be positioned using the Frankfurt horizontal (a line joining the orbitale and the porion) [Farkas, 1981]. Here we define the anatomic features important in proposing the Definitions of the paper.

Anatomy

Lips: The structures that surround the oral aperture (Fig. 1). In the central region their superior border corresponds to the inferior margin of the base of the nose. Laterally, their limits follow the alar sulci and the upper and lower lips join at the oral commissures. The inferior limit of the lips in the central region is the mentolabial sulcus. Anatomically, the philtrum and its pillars are a part of the upper lip. The surface of the lip is comprised of four zones: hairy

*Correspondence to:

John C. Carey, Division of Medical Genetics, 419 Wakara Way Suite 213, Salt Lake City, UT 84108. E-mail: john.carey@hsc.utah.edu

Published online 5 January 2009 in Wiley InterScience

(www.interscience.wiley.com)

DOI 10.1002/ajmg.a.32602

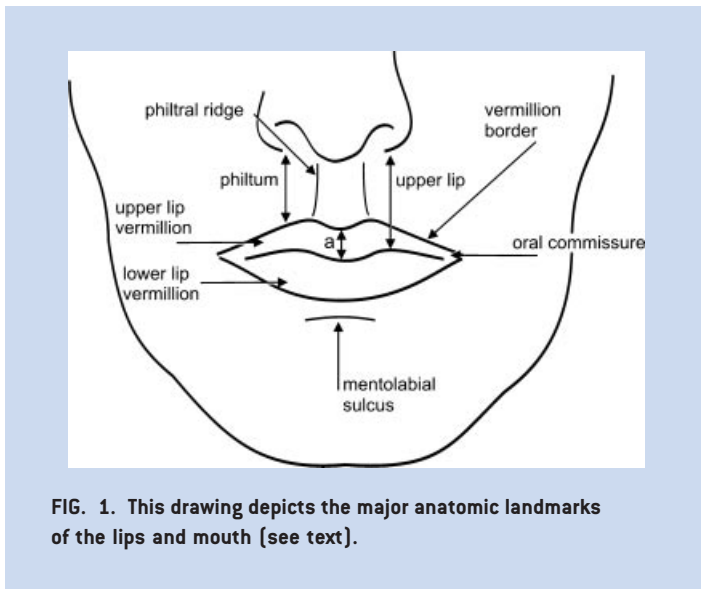


FIG. 1. This drawing depicts the major anatomic landmarks of the lips and mouth (see text).

skin, vermillion border, vermillion and oral mucosa. The normal shape of the lips varies with age, and is influenced by ethnicity.

Vermilion: The red part of the lips (Fig. 1). It is covered with a specialized stratified squamous epithelium, which is in continuity with the oral mucosa of the gingivolabial groove. Confusingly, the vermillion itself is also often referred to as “the lips.”

Vermilion border: The rim of paler skin that demarcates the vermillion from the surrounding skin.

Cupid’s bow: The contour of the line formed by the vermillion border of the upper lip. In a frontal view, this line resembles an archer’s bow, which curves medially and superiorly from the commissures to the paramedian peaks located at the bases of the pillars of the philtrum (crista philtrae) with an inferior convexity lying between those peaks. The philtrum is the vertical groove in the midline of the upper lip bordered by these lateral pillars (ridges) [Hennekam et al., 2009].

Oral mucosa: Stratified squamous non-keratinized epithelium covering of the inner aspect of the oral cavity [Standing, 2005].

Mouth: The oral aperture that opens into the oral cavity proper [Standing, 2005]. The opening is bounded by the upper and lower vermillion. The cavity comprises the alveolar arches with gums and teeth, the hard and soft palate, and the tongue, anchored to the floor of the mouth (Fig. 2). The oral cavity leads into the oropharynx, bounded by the tonsillar pillars. Standards exist for measuring the length and height of the oral aperture [Farkas, 1981].

Oral commissure: The place where the lateral aspects of the vermillion of the upper and lower lips join. The cheilion is the anthropological landmark located at this site (see Fig. 1).

Labial fissure: Slit-like space between the lips; the oral vestibule.

Oral Cavity: The space bounded superiorly by the hard and soft palates, laterally by the alveolar processes of the maxillary bone, and inferiorly by the tongue (see Fig. 2).

Alveolar ridge: The U-shaped bony crests of the upper and lower jaw in which the teeth are situated.

Hard palate: Bony anterior two-thirds of the roof of the mouth separating the nasal cavity from the oral cavity. The boundary of the hard and soft palates can be determined by palpation.

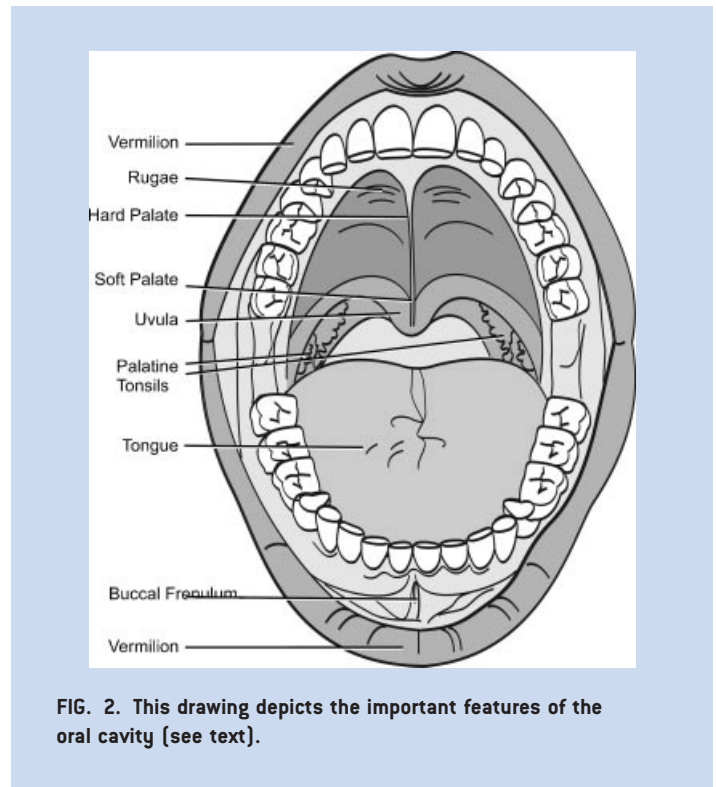


FIG. 2. This drawing depicts the important features of the oral cavity (see text).

Soft palate (*velum palatinum*): Posterior one third of the palate comprised of a fibromuscular fold of soft tissue suspended from the hard palate and separating the nasal and oral cavities.

Uvula: A conical projection of soft tissue extending inferiorly from the posterior edge of the middle of the soft palate (see Fig. 2).

Gingiva (gums): Dense fibrous tissue covered by mucous membrane overlying the alveolar ridge in which the teeth are situated.

Buccal frenulum: A thin fold of soft tissue extending from the gingiva of the mid-anterior alveolar ridge to the inner surface of the medial part of the upper or lower lip (see Fig. 2).

Lingual frenulum: A thin fold of soft tissue extending from the floor of the mouth to the base of the tongue.

Tongue: Muscular organ of deglutition, speech and taste covered with epithelium and bound to the floor of the mouth.

Teeth: Hard dental structures located on the alveolar ridges and situated in the gingiva. In humans, teeth have two stages, the primary (deciduous) and the secondary (permanent, adult).

LIPS: DEFINITIONS

Commissural Pit

Definition: Depression located at an oral commissure (Fig. 3).
objective

Comments: This pit has no relationship to a *Lip pit*.

Cupid’s bow: see *Cupid’s bow, exaggerated*

Cupid’s bow, accentuated: see *Cupid’s bow, exaggerated*

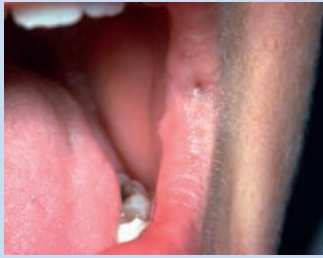

FIG. 3. *Commissural pit*. These are always located at the same position at the corners of the oral aperture.

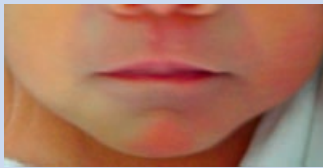


FIG. 4. *Absent Cupid's bow*. This feature is often associated with a thin vermilion of the upper lip as in this child.

Cupid's Bow, Absent

Definition: Lack of paramedian peaks and median notch of the upper lip vermilion (Fig. 4). *objective*

Comment: This bow is often absent in a *Thin vermilion of the upper lip*, but that should be assessed separately. This finding is commonly associated with *Smooth philtrum*, but that should be coded separately [Hennekam et al., 2009].

Cupid's Bow, Exaggerated

Definition: More pronounced paramedian peaks and median notch of the Cupid's bow (Fig. 5). *subjective*

Comment: This may be associated with a *Deep philtrum*, [Hennekam et al., 2009] but that finding should be coded separately.

Synonym: Cupid's bow, accentuated

Replaces: Cupid's bow (used without adjective)

Lip fistula: see *Lip pit*

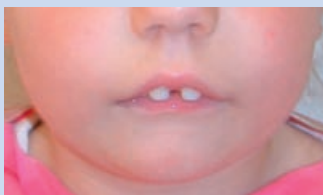


FIG. 5. *Exaggerated Cupid's bow*.

Lip Freckle

Definition: Increased focal pigmentation of the vermilion of the lips (Fig. 6). *subjective*

Comment: Lip freckles may be accompanied by *Perioral hyperpigmentation*, but this should be assessed separately. Lentigo is commonly used as a synonym for freckle in reference to the vermilion, but these are distinct terms when referring to the skin.

Synonym: Lip lentigo

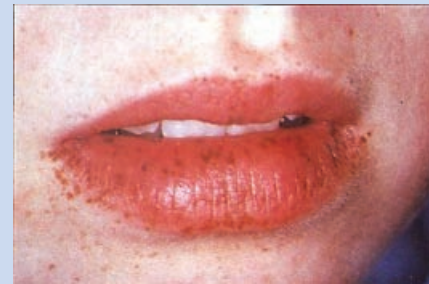

FIG. 6. *Freckling of the vermilion of the lower lip*.

Lip, coarse: see, *Vermilion, upper lip, thick*

Lip, full: see *Vermilion, upper lip, thin*

Lip, lentigo: see *Lip freckle*

Lip, lower drooping: see *Vermilion, lower lip, everted*

Lip, lower full: see *Vermilion, lower lip, thick*

Lip, lower thick: see *Vermilion, lower lip, thick*

Lip Pit

Definition: Depression located on the vermilion of the lower lip, usually paramedian (Fig. 7). *objective*

Comments: A lip pit may be connected by a fistula to mucous minor salivary glands in the lower lip. In addition, a lip pit may on occasion be seen with a surrounding tissue elevation (mound). Pits located at the labial commissure (cheilion) are distinct from lip pits; see *Commissural pit*.

Synonym: Lip fistula

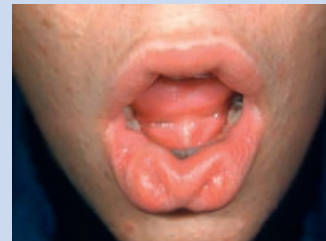

FIG. 7. *Typical lip pits*. Note: these are usually just lateral to the midline.

Lip, thick: see *Vermilion, upper lip, thin* Lip, upper thin: see *Vermilion, upper lip, thin*

Mouth, tented: see *Vermilion, upper lip, tented*

Nasolabial crease, hypoplastic: see *Nasolabial fold, underdeveloped*

Nasolabial crease, prominent: see *Nasolabial fold, prominent*

Nasolabial crease, underdeveloped: see *Nasolabial fold, underdeveloped*

Nasolabial Fold, Prominent

Definition: Exaggerated bulkiness of the crease or fold of skin running from the lateral margin of the nose, where nasal base meets the skin of the face, to a point just lateral to the corner of the mouth (cheilion, or commissure) (Fig. 8). *subjective*

Comments: Increasing prominence with age is usual. See Allanson et al. [2009b].

Synonym: Nasolabial crease, prominent

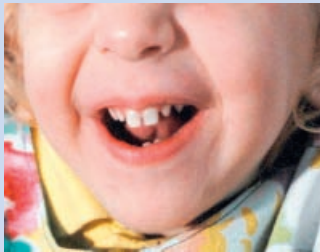

FIG. 8. Prominent nasolabial fold.

Nasolabial Fold, Underdeveloped

Definition: Reduced bulkiness of the crease or fold of skin running from the lateral margin of the nose, where nasal base meets the skin of the face, to a point just lateral to the corner of the mouth (cheilion or commissure) (Fig. 9). *subjective*

Comments: See Allanson et al. [2009b].

Synonym: Nasolabial crease, underdeveloped

Replaces: Nasolabial crease, hypoplastic; Nasolabial fold, hypoplastic

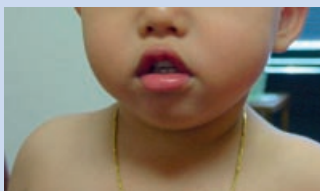


FIG. 9. Underdeveloped nasolabial fold.

Perioral Hyperpigmentation

Definition: Increased pigmentation, either focal or generalized, of the skin surrounding the vermilion of the lips (Fig. 10). *subjective*

Comment: Periorbital hyperpigmentation may be accompanied by *Lip freckles*, but this should be assessed separately.

Vermilion border, thin: see *Vermilion, upper lip, thin*

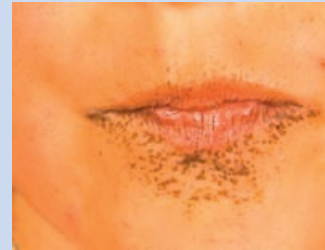

FIG. 10. Perioral hyperpigmentation.

Vermilion, Lower Lip, Everted

Definition: Inner aspect of the lower lip vermilion (normally apposing the teeth) visible in a frontal view (Fig. 11). *subjective*

Comments: In frontal view, with the face relaxed, the apparent height of the lower lip vermilion is excessive and the lower incisors may be visible. On profile view, the vermilion is more convex than usual. An everted lower lip may be viewed as “pouting,” but this designation is a functional term.

Replaces: Drooping lower lip

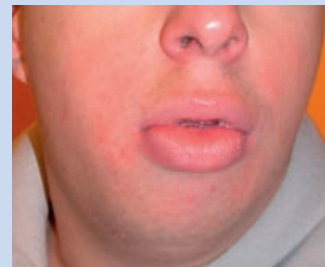


FIG. 11. Everted vermilion of the lower lip. The designation pouting lower lip is sometimes used but this is a functional term.

Vermilion, Lower Lip, Thick

Definition: Height of the vermilion of the lower lip in the midline more than 2 SD above the mean (Fig. 12). *objective*

OR apparently increased height of the vermilion of the lower lip in the frontal view. *subjective*

Comments: Normal values for the height of the vermilion are available [Farkas, 1981] but measurements are not commonly used. Most clinicians determine this feature subjectively. The lower lip is

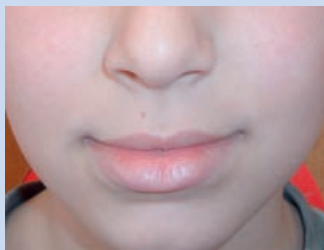


FIG. 12. *Thick vermilion of the lower lip.*

typically thicker than the upper one. The height of the vermilion of the lower lip varies among ethnic groups, and the vermilion should be compared to a population of same ethnic background. When the vermilion is thick, it is more convex and more everted than usual on profile view, but that should be assessed separately.

Replaces: Thick lower lip; Full lower lip

Vermilion, Lower Lip, Thin

Definition: Height of the vermilion of the medial part of the lower lip more than 2 SD below the mean (Fig. 13). *objective*

OR apparently reduced height of the vermilion of the lower lip in the frontal view. *subjective*

Comment: Normal values for the height of the vermilion are available [Farkas, 1981] but measurements are not commonly used. Most clinicians determine this feature subjectively. The height of the vermilion of the lower lip varies considerably among ethnic groups, and the vermilion should be compared to a population of same ethnic background. If the lower lip vermilion is thin, the inferior border of the vermilion is less curved, and on a profile view, the lower lip vermilion is less convex than usual.

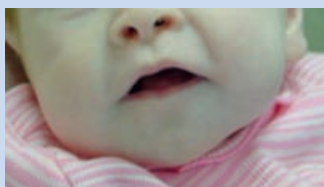

FIG. 13. *Thin vermilion of the lower lip.*

Vermilion, Upper Lip, Everted

Definition: Inner aspect of the upper lip vermilion (normally apposing the teeth) visible in a frontal view (Fig. 14). *subjective*

Comments: In frontal view, with the face relaxed, the apparent height of the upper lip vermilion is excessive and the upper incisors may be visible. On profile view, the vermilion is more convex than usual. An everted upper lip may be associated with a short philtrum, and may be secondary to protruded upper teeth, but these should be assessed and described separately.

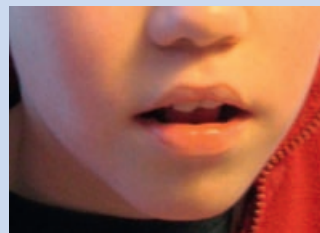


FIG. 14. *Everted vermilion of the upper lip.*

Vermilion, Upper Lip, Tented

Definition: Triangular appearance of the oral aperture with the apex in the midpoint of the upper vermilion and the lower vermilion forming the base (Fig. 15). *subjective*

Comment: This finding is distinguished from an *Exaggerated Cupid's bow* by the alteration of the shape of the oral aperture.

Replaces: Tented mouth

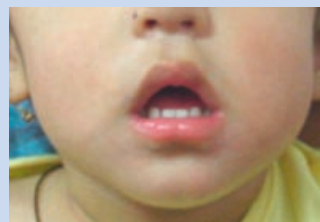

FIG. 15. *Tented vermilion of the upper lip.*

Vermilion, Upper Lip, Thick

Definition: Height of the vermilion of the upper lip in the midline more than 2 SD above the mean (Fig. 16). *objective* OR

apparently increased height of the vermilion of the upper lip in the frontal view. *subjective*

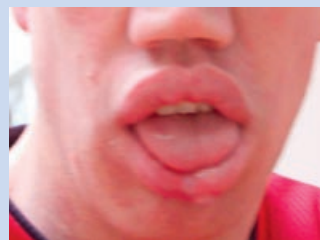


FIG. 16. *Thick vermilion of the upper lip.* This is the preferred designation rather than coarse or full lip since the described feature is the vermilion of the lip, not the lip itself.

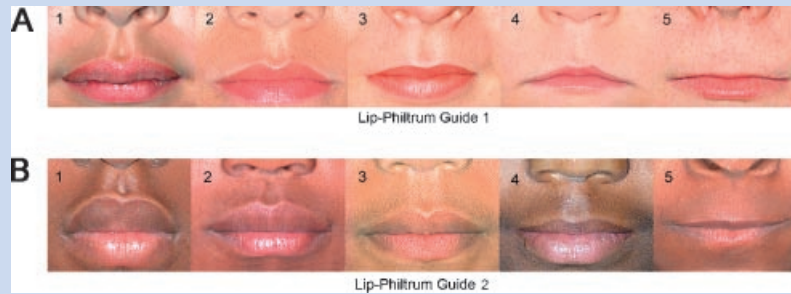

FIG. 17. This figure displays the commonly used Likert scale, 1–5, that ranges from the *Thick vermillion of the upper lip* [1] to *Thin vermillion*; in a Caucasian (A) and an African-American (B) [see text]. Note as well the philtral scale from 1 to 5 [see Hennekam et al., 2009].

Comments: Normal values for the height of the vermillion are available [Farkas, 1981], but measurements are not commonly used. Most clinicians determine this feature subjectively or utilize the Likert scale of Astley and Clarren [2000] (Fig. 17). The vermillion of the upper lip varies considerably among ethnic groups, and the vermillion should be compared to a population of same ethnic background. The thickness of the upper lip vermillion is sensitive to the facial expression. On profile view, a thick vermillion is more convex than usual.

Replaces: Coarse lip; Thick lip; Full lip

Vermilion, Upper Lip, Thin

Definition: Height of the vermillion of the upper lip in the midline more than 2 SD below the mean (Fig. 18). *objective*

OR apparently reduced height of the vermillion of the upper lip in the frontal view. *subjective*

Comments: Normal values for the height of the vermillion are available [Farkas, 1981], but measurements are not commonly used. Most clinicians determine this feature subjectively or use the Likert scale for Caucasians and African Americans [Astley and Clarren, 2000] (see Fig. 17). The height of the vermillion of the upper lip varies among ethnic groups, and the vermillion should be compared to a population of same ethnic background. The thinness of the upper lip vermillion is sensitive to facial expression (see Anatomy Section). On profile view, a thin vermillion is less convex than usual. A thin upper lip vermillion may be associated with a smooth philtrum and an absence of the Cupid's bow, but these should be assessed separately.

Replaces: Thin vermillion border; Thin upper lip

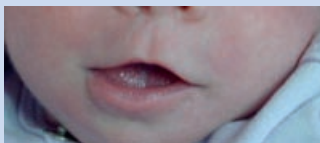


FIG. 18. *Thin vermillion of the upper lip*. Note the *absent Cupid's bow* as well.

MOUTH: DEFINITIONS

Alveolar ridge fusion: see *Fibrous syngnathia*

Fibrous Syngnathia

Definition: Complete or nearly complete soft tissue fusion of the alveolar ridges (Fig. 19). *subjective*

Comments: This finding is associated with severely reduced mobility, or lack of mobility, between the upper and lower jaws. This finding is the severe end of a spectrum that includes *Oral synechia*.

Synonym: Fusion of the alveolar ridges

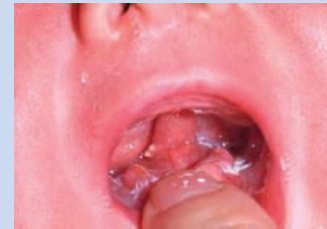

FIG. 19. *Fibrous syngnathia*. See *Oral synechia* as well.

Hyperpigmentation, Intra-Oral

Definition: Increased pigmentation, either focal or generalized, of the oral mucosa (Fig. 20). *subjective*

Comment: Pigmentation of alveolar ridges is common in people with dark skin pigmentation. This term encompasses a range of pigmentary findings, from freckles to generalized hyperpigmentation.

Macrostomia: see *Mouth, wide*

Microstomia: see *Mouth, narrow*

Mouth, carp: see *Mouth, downturned corners of*

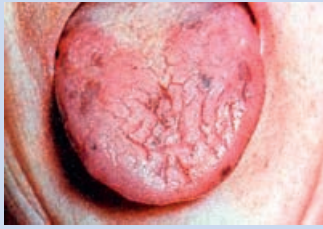

FIG. 20. *Intra-oral hyperpigmentation.*

Mouth, Downturned Corners of

Definition: Oral commissures positioned inferior to the midline labial fissure (Fig. 21). *subjective*

Comment: This finding should be assessed with the mouth closed, the lips in relaxed contact, and the face relaxed. The finding may be difficult to assess if the lower lip is enlarged.

Replaces: Carp mouth; Fish mouth (pejorative terms)

Mouth, fish: see *Mouth, downturned corners of*

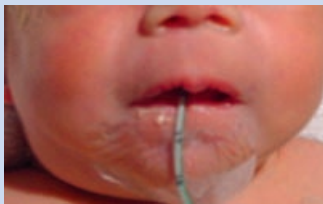

FIG. 21. *Downturned corners of the mouth.* Here the oral commissures are positioned inferior to the midline labial fissure.

Mouth, Narrow

Definition: Distance between the commissures more than 2 SD below the mean (Fig. 22). *objective*

or apparently decreased width of the oral aperture. *subjective*

Comment: The width of the mouth varies with facial movement and must be assessed when the subject has a relaxed (neutral) face. This term replaces microstomia, small oral aperture, and small mouth because the reduced opening of the mouth is secondary to reduced width.

Replaces: Microstomia; Small oral aperture; Small mouth

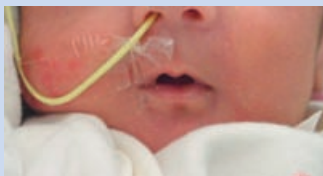

FIG. 22. *Narrow mouth.*

Mouth, Upturned Corners of

Definition: Oral commissures positioned superior to the midline labial fissure (Fig. 23). *subjective*

Comment: This finding should be assessed with the mouth closed, the lips in relaxed contact, and the face relaxed. The finding may be difficult to assess if the upper lip is enlarged.

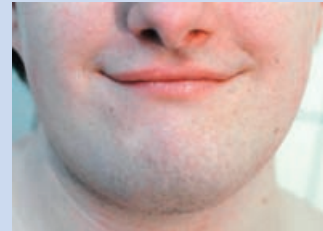


FIG. 23. *Upturned corners of the mouth.*

Mouth, Wide

Definition: Distance between the oral commissures more than 2 SD above the mean. *objective* OR

apparently increased width of the oral aperture (Fig. 24). *subjective*

Comment: The width of the mouth varies with facial movement and must be assessed when the subject has a relaxed (neutral) face. This term replaces macrostomia, large mouth, and large oral aperture because these terms imply a wide and open mouth. The term should not be used to describe a patient with a lateral oral cleft.

Replaces: Macrostomia; Large mouth; Large oral aperture



FIG. 24. *Wide mouth.* This width of the oral aperture can be easily measured.

Oral aperture, small: see *Mouth, narrow*

Oral Frenulum, Accessory

Definition: Extra fold of tissue extending from the alveolar ridge to the inner surface of the upper or lower lip (Fig. 25). *objective*

Comment: This finding is assessed by gently retracting the oral mucosa from the alveolar ridge. Typically there is a single maxillary and a single mandibular frenulum located in the midline between the two central incisors. Abnormalities of the alveolar ridges may

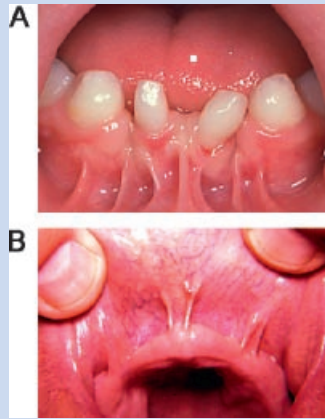


FIG. 25. Accessory oral frenulum of the lower (A) and upper lips (B) in different patients.

accompany accessory frenula, but these should be assessed separately.

Synonyms: Supernumerary oral frenulum; Extra oral frenulum

Oral frenulum, extra: see *Oral frenulum, accessory*

Oral frenulum, supernumerary: see *Oral frenulum, accessory*

Oral Synechia

Definition: Fibrous band between the mucosal surfaces of the upper and lower alveolar ridges (Fig. 26). *objective*

Comment: These bands must be distinguished from synechia between the tongue and palate (glossopalatal ankylosis) and from synechia arising from the floor of the mouth (as in the subglossopalatal membrane), oropharyngeal isthmus (as in persistent buccopharyngeal membrane) or from the lower lip [Gorlin et al., 2001]. If there is a complete soft tissue contiguity between the upper and lower alveolar ridges, the term, *Fibrous syngnathia* should be used instead.

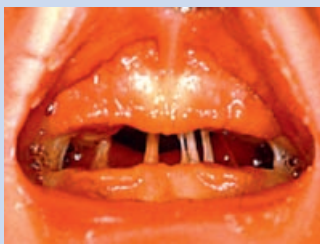

FIG. 26. Oral synechia. Note the obvious fibrous bands.

Vermilion, Upper Lip, U-Shaped

Definition: Gentle upward curve of the upper lip vermilion such that the center is placed well superior to the commissures (Fig. 27). *subjective*

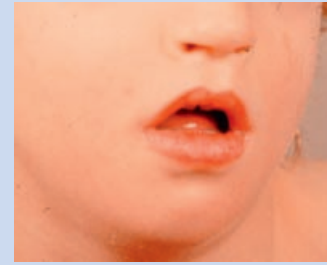


FIG. 27. U-shaped vermilion of the upper lip. Note the contour of the vermilion and the shape of the oral aperture.

Comment: The U-shaped upper vermilion is a more rounded version of the *Tented upper lip vermilion*. In U-shaped upper vermilion there is loss of the central groove of the Cupid's bow.

Replaces: Carp mouth; Fish mouth (pejorative terms); U-shaped mouth

ORAL CAVITY: DEFINITIONS

Aglossia: see *Tongue, small*

Alveolar ridge hypertrophy: see *Alveolar ridge overgrowth*

Alveolar Ridge Overgrowth

Definition: Increased width of the alveolar ridges (Fig. 28). *subjective*

Comments: This finding may or may not be accompanied by increased height of the alveolar ridge. This is not to be confused with *Prominent palatal ridges* or *Gingival overgrowth*. This distinction of gingival from alveolar ridge overgrowth may be difficult, especially in milder degrees of the finding.

Replaces: Alveolar ridge hypertrophy

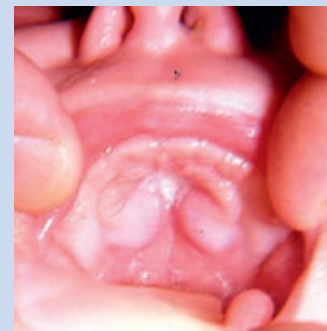

FIG. 28. Alveolar ridge overgrowth. Note the increased width of the alveolar ridge.

Ankyloglossia

Definition: Short or anteriorly attached lingual frenulum associated with limited mobility of the tongue (Fig. 29). *subjective*

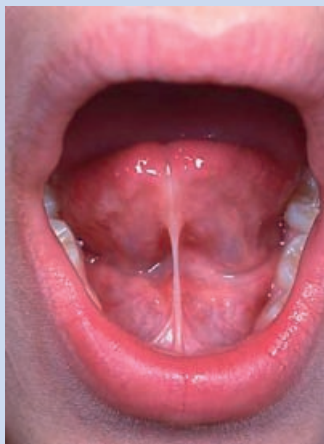

FIG. 29. *Ankyloglossia*. Note the accompanying short lingual frenulum and mild indentation of the tongue tip.

Comment: The anterior third of the tongue is usually free or is partially attached to the floor of the mouth by the lingual frenulum. There is a spectrum ranging from fusion of the tongue to the floor of the mouth (“ankyloglossia inferiorum”) to a lingual frenulum that is short or anchored toward the tip of the tongue (“tongue tie”). Ankyloglossia may be associated with a mild indentation of the tip of the tongue, which should not be coded as a *Bifid tongue*.

Replaces: Ankyloglossia inferiorum; tongue tie

Anodontia: see *Oligodontia*

Central Incisor, Single Maxillary

Definition: Presence of one maxillary central incisor positioned in the midline (Fig. 30). *objective*

Comment: If a single maxillary central incisor is present but not positioned in the midline, this could be hypodontia (see *Ologodontia*), but this cannot be evaluated without a radiograph.

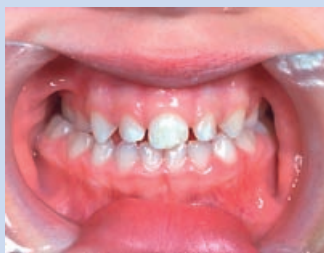

FIG. 30. *A single central maxillary incisor*. The lateral incisors are normal making the recognition of this feature difficult on first glance.

Dental Crowding

Definition: Overlapping teeth within an alveolar ridge (Fig. 31). *subjective*

Comment: This is a bundled term. There is a discrepancy in the size or number of the teeth compared to the size of the alveolar ridges.

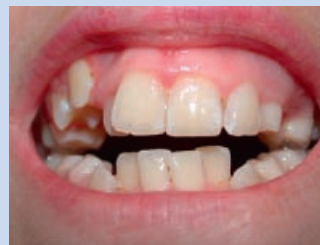

FIG. 31. *Dental crowding*.

Diastema

Definition: Increased space between two adjacent teeth in the same dental arch (Fig. 32). *subjective*

Comments: Usually there is contact between the lateral aspects of the permanent teeth, at their broadest point. Diastema can apply to any pair of teeth and the term should be modified by a descriptor of the involved teeth. This descriptor must be distinguished from *Widely spaced teeth*.

Diastemata, multiple: see *Teeth, widely spaced*

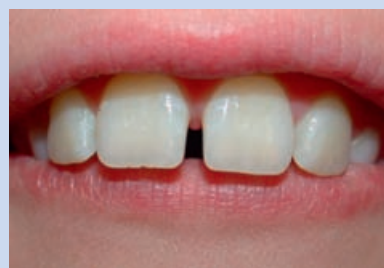

FIG. 32. *Diastema*. See *widely spaced teeth* as well.

Double tooth: see *Teeth, fused*

Eruption, Advanced

Definition: Tooth eruption more than 2 SD earlier than the mean eruption age. *objective*

Comment: There are established norms for the timing of eruption in both deciduous and permanent teeth [Garn and Rohmann, 1966; Lunt and Law, 1974; McDonald et al., 2004]. Eruption is defined by the appearance of a tooth that has pierced the gum.

Eruption, Delayed

Definition: Tooth eruption more than 2 SD beyond the mean eruption age. *objective*

Comment: This term should not be used in a patient with **Gingival overgrowth**. There are established norms for the timing of eruption in both deciduous and permanent teeth [Garn and Rohmann, 1966; Lunt and Law, 1974; McDonald et al., 2004]. Eruption is defined by the appearance of a tooth that has pierced the gum.

Gingival hyperplasia: see **Gingival overgrowth**

Gingival hypertrophy: see **Gingival overgrowth**

Gingival Overgrowth

Definition: Thickening of the soft tissue overlying the alveolar ridge (Fig. 33). *subjective*

Comments: The degree of thickening ranges from involvement of the interdental papillae alone to gingival overgrowth covering the entire tooth crown.

Replaces: Gingival hypertrophy, Gingival hyperplasia

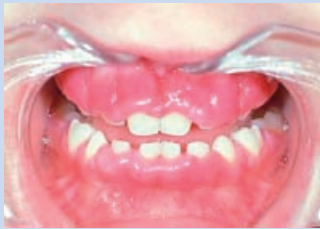

FIG. 33. **Gingival overgrowth**. Note the difference between this finding and overgrowth of the alveolar ridge.

Glossoptosis

Definition: Posterior displacement of the tongue into the pharynx (Fig. 34). *subjective*

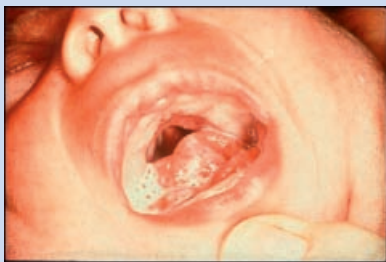

FIG. 34. **Glossoptosis**. Note the tongue's posterior placement in the oral cavity and the presence of the formula. [Figure courtesy of Bryan Hall.]

Comment: Presumably, use of the suffix “ptosis” refers to the situation where the patient is supine, and the displacement is downward. Strictly speaking, the term glossoptosis indicates “falling” of the tongue and thus can also be forward displacement; however by convention it is only used for backward displacement. Glossoptosis may cause obstruction of the airway.

Hypodontia: see **Oligodontia**

Hypoglossia: see **Tongue, small**

Macrodonia

Definition: Mesiodistal tooth diameter (width) more than 2 SD above mean for age (Fig. 35). *objective* OR

apparently increased maximum width of the tooth. *subjective*

Comment: The standard reference has means and standard deviations by gender [Moyers et al., 1976].

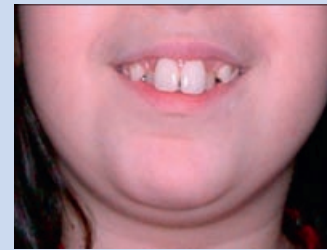


FIG. 35. **Macrodonia**. The tooth width is easily measured.

Macroglossia: see **Tongue, large**

Microdonia

Definition: Mesiodistal tooth diameter (width) more than 2 SD below mean (Fig. 36). *objective*

OR apparently decreased maximum width of tooth. *subjective*

Comment: Standard reference has means and standard deviations by gender [Moyers et al., 1976]. In microdonia, the gaps between the teeth, particularly the anterior upper and lower teeth, are increased, creating **Diastemata**. This should be assessed and coded separately.

Microglossia: see **Tongue, small**

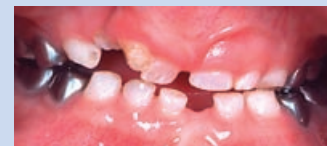

FIG. 36. **Microdonia**.

Oligodontia

Comment: The term is not defined here since the finding requires a radiograph, as is true for anodontia and for the other designation of tooth agenesis, hypodontia. The terms hypodontia and oligodontia are sometimes used interchangeably in the literature while on other occasions hypodontia is used for selective agenesis of six or less missing teeth while oligodontia is applied when there are more than six missing teeth. Tooth agenesis or oligodontia/hypodontia can be mistaken for delayed eruption and again a radiograph is needed for diagnosis. Absence of teeth may be congenital (tooth agenesis) or acquired. The incidence of congenital absence of teeth is different depending on the type and position of the tooth [Gorlin et al., 2001].

Open Bite

Definition: Visible space between the dental arches in occlusion (Fig. 37). *objective*

Comments: An open bite produces an absence of vertical overlap of the two dental arches. It may be associated with malocclusion, but this should be coded separately. Open bite can be accompanied by malocclusion, which is a complex bundled term. The Angle classification of malocclusion (Classes I–III) is widely used in the orthodontics community [Moyers, 1973] for the characterization of malocclusion.

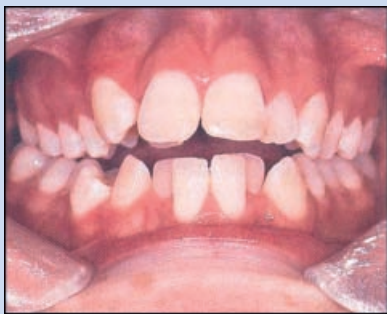

FIG. 37. *Open bite*. Note the space between the dental arches. [Figure courtesy of Duane Yamashiro.]

Palate, Hard, Short

Definition: Distance between the labial point of the incisive papilla to the midline junction of the hard and soft palate more than 2 SD below the mean (Fig. 38). *objective*

or apparently decreased length of the hard palate. *subjective*

Comment: Objective measurement of the hard palate requires special instrumentation [Hall et al., 2006]. A short hard palate may be associated with velopharyngeal incompetence.

Replaces: Short palate; hypoplastic palate

Palate, short: see *Palate, hard, short*

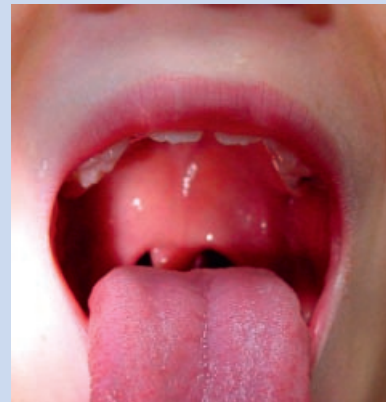


FIG. 38. *Short hard palate*. [Figure courtesy of Alan Rope.]

Palate, High

Definition: Height of the palate more than 2 SD above the mean. *objective* OR

Palatal height at the level of the first permanent molar more than twice the height of the teeth (Fig. 39). *subjective*

Comments: The measuring device for this assessment is described in Hall et al. [2006]. A high palate is often associated with a narrow palate. However, a narrow palate can easily give a false appearance of a high palate. Height and width of the palate should be assessed and coded separately. We do not recommend the subjective determination because this term can be overused and applied inaccurately.

Synonym: High, arched palate

Palate, high arched: see *Palate, high*

Palate, hypoplastic: see *Palate, hard, short*

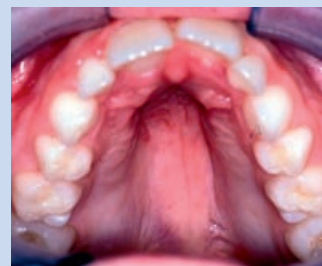

FIG. 39. *High palate*. Note a narrow palate is a different feature and can produce the false appearance of a high palate.

Palate, Narrow

Definition: Width of the palate more than 2 SD below the mean. *objective*

OR apparently decreased palatal width (Fig. 40). *subjective*

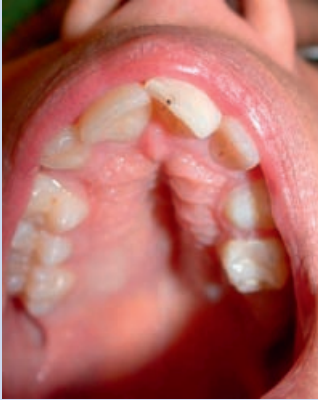

FIG. 40. Narrow palate. Note *Prominent palatine ridges* as well.

Comments: Palatal width is measured as the distance between the maxillary first permanent molar on the right and left sides, at the lingual cervical line, using a specific device. Palate width is typically assessed subjectively in routine clinical practice. Narrowing is often associated with a *High palate*, but this should be assessed and coded separately. *Gingival overgrowth* can give the impression of a narrow palate but should be distinguished and coded separately. The term “gothic palate” is used to indicate that the roof of the palate is not round but rather has an inverted V-shape, and therefore, only the upper part of the palate is narrow.

Palate, Submucous Cleft

Definition: Soft palatal defect with intact overlying mucosa comprising two of the following three findings: (1) notching of the posterior border of the hard palate, (2) bifid uvula, or (3) muscular diastasis leading to a midline translucent zone or furrow in the soft palate (Fig. 41). *objective*

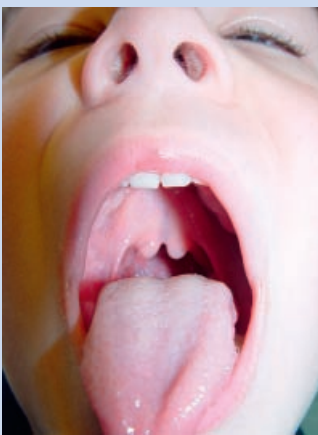


FIG. 41. *Submucous cleft palate*. Note the *Cleft uvula* and the blue indentation of the soft palate. [Figure courtesy of Robert Shprintzen.]

Comment: The notch of the posterior hard palate can sometimes be palpated [Aase, 1990]. Submucous cleft palate is a bundled term but because of its common usage is included here.

Palatine Ridges, Prominent

Definition: Increased size and/or number of soft tissue folds on the palatal side of the maxillary alveolar ridge (Fig. 42). *subjective*

Comments: Soft tissue folds are typically present on the lateral sides of the palate, especially anteriorly.

Synonym: Prominent lateral palatal ridges; Prominent palatine folds

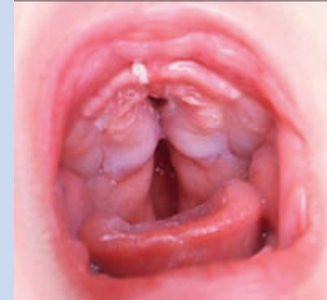

FIG. 42. *Prominent palatine ridges*. Note the more obvious soft tissue ridges and folds.

Teeth, Fused

Comments: Dental fusion or double tooth (the joining of teeth with separate roots) can only be distinguished from gemination (bifid crown, where only one pulp chamber or root canal is present), with radiographic evidence [Cameron and Widmer, 2003]. Therefore this term is not defined here.

Teeth, Widely Spaced

Definition: Increased spaces (diastemata) between most of the teeth in the same dental arch (Fig. 43). *subjective*

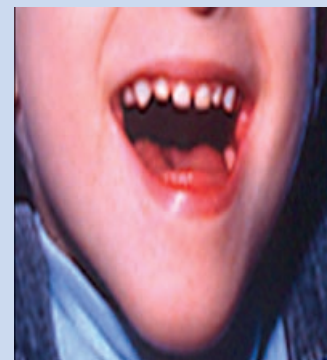


FIG. 43. *Widely spaced teeth*.

Comments: Wide spacing can be secondary to increased room by an unusually large dental arch, microdontia or mixed primary and secondary dentition. It should be carefully noted that slight spacing between the primary teeth is normal, so experience in evaluation is important in determining this feature. This descriptor must be distinguished from *Diastema*.

Synonym: Multiple diastemata

Tongue, Bifid

Definition: Tongue with a median apical indentation or fork (Fig. 44). *objective*

Comments: Bifid tongue can be associated with *Ankyloglossia*, but this should be assessed and coded separately. Small indentations of the tip of the tongue should not be coded as a bifid tongue.

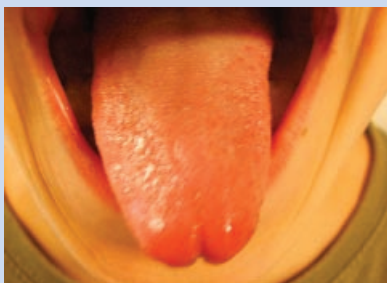


FIG. 44. Bifid tongue.

Tongue, Furrowed

Definition: Accentuation of the grooves on the dorsal surface of the tongue (Fig. 45). *subjective*

Comments: Usually there is a midline groove with smaller radiating grooves. The deep furrows may extend to the lateral borders. They may follow a regular geometric pattern or be irregular. A furrowed tongue occurs in 10–25% of individuals but is rare in children.

Synonyms: Prominent tongue grooves

Replaces: Scrotal tongue (pejorative)

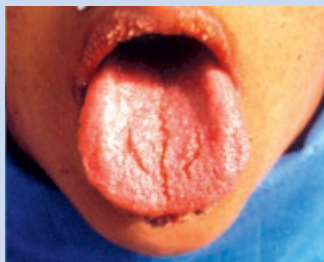

FIG. 45. Furrowed tongue.

Tongue grooves, prominent see *Tongue furrowed*

Tongue, hyperplasia: see *Tongue, large*

Tongue, hypertrophy: see *Tongue, large*

Tongue, hypoplastic: see *Tongue, small*

Tongue, Large

Definition: Increased length and width of the tongue (Fig. 46). *subjective*

Comments: Normal standards do not exist. Large size usually leads to protrusion of the tongue. This is an acknowledged bundled term, but due to its frequent usage and relative paucity of situations that would call for separate individual assessments of tongue dimensions, the bundled term is retained. *Micrognathia* may give the false appearance of a large tongue.

Synonyms: Macroglossia; hyperplasia of the tongue; hypertrophy of the tongue

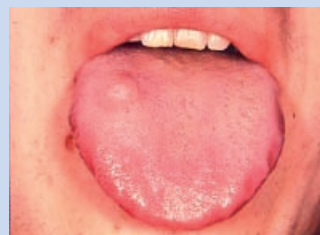

FIG. 46. Large tongue.

Tongue, Lobulated

Definition: Multiple indentations and/or elevations on the edge and/or surface of the tongue producing an irregular surface contour (Fig. 47). *subjective*

Comment: Lobulated tongue can bilobed, trilobed, or show multiple lobes.

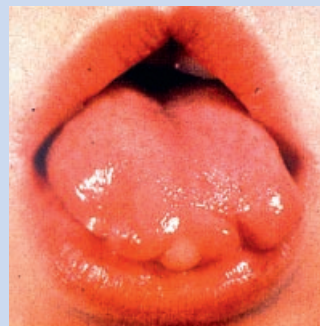


FIG. 47. Lobulated tongue.

Tongue, Protruding

Definition: Tongue extending beyond the alveolar ridges or teeth at rest (Fig. 48). *subjective*

Comments: *Protruding tongue* may or may not be associated with a *Large tongue*, and that finding should be assessed and coded separately.

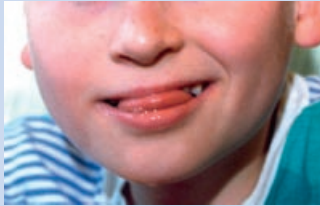

FIG. 48. *Protruding tongue*. Note the position of the tongue.

Tongue, rudimentary: see *Tongue, small*

Tongue, scrotal: see *Tongue, furrowed*

Tongue, Small

Definition: Decreased length and width of the tongue (Fig. 49). *subjective*

Comment: Normal standards do not exist. The term “aglossia” is often used for extremely small tongue, but a nubbin of tongue tissue is almost always present and aglossia *in sensu strictu* is extremely rare. This is an acknowledged bundled term, but due to its frequent usage and relative paucity of situations that would call for separate individual assessments of tongue dimensions, the bundled term is retained.

Synonyms: Microglossia; hypoglossia; rudimentary tongue

Replaces term: Aglossia; hypoplastic tongue; hypotrophic tongue

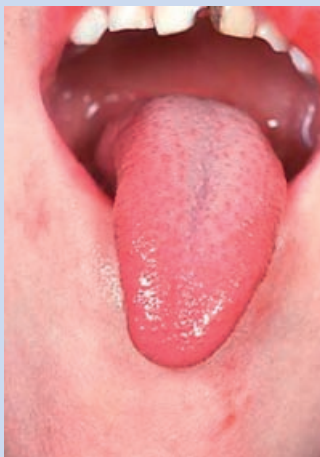


FIG. 49. *Small tongue*.

Tongue, Smooth

Definition: Glossy appearance of the entire tongue surface (Fig. 50). *subjective*

Comment: This is due to reduction in number and/or size of the filiform papillae. A geographic tongue has localized areas of smoothing, but not sufficient to warrant use of the term *Smooth tongue*.

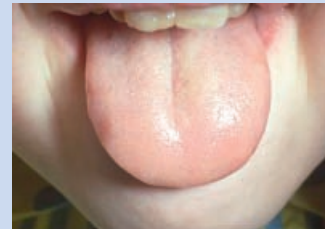

FIG. 50. *Smooth tongue*. Note the surface of the tongue in this patient.

Tooth agenesis: see *Oligodontia*

Tooth, Natal

Definition: Erupted tooth or teeth at birth (Fig. 51). *objective*

Comment: This is not to be confused with apical dental cysts. Natal teeth most often involve lower central incisors, less often upper central incisors, and rarely first primary molars. Natal teeth occur about once in 3,000 births and are particularly common among some native (First Nation) groups of North America [Mok and Suina, 1986].

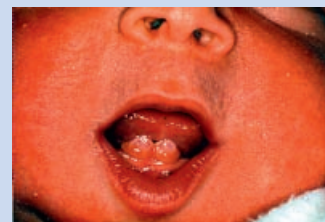


FIG. 51. *Natal tooth*. Note the eruption of this tooth in this newborn infant.

Tooth, Premature Loss

Definition: Exfoliation of a primary tooth or teeth earlier than the normal range. *objective*

Comments: See ranges in Kleigman et al. [2007] and Gorlin et al. [2001]. The range of ages in years for normal exfoliation of primary teeth usually precedes the mean age of eruption of each tooth by a year or less.

Tooth, Supernumerary

Definition: Extra tooth or teeth (Fig. 52). *objective*

Comment: The most frequent supernumerary tooth is a mesiodens, which occurs between the two maxillary central incisors. Often it fails to erupt, but creates a large anterior diastema, and would not be detected on physical examination (requires X-ray evaluation). This designation excludes coexistence of primary and permanent dentition due to delayed loss of the former.

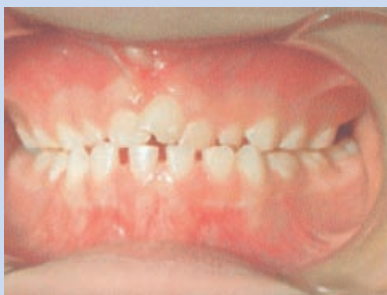

FIG. 52. *Supernumerary tooth*. Note the extra central incisor between the other incisors. Also there are some *widely spaced teeth* in the lower arch. (Figure courtesy of Duane Yamashiro.)

Uvula, Absent

Definition: Lack of the uvula (Fig. 53). *objective*

Comment: Sometimes accompanies a *Submucous cleft palate*, but this should be coded separately.

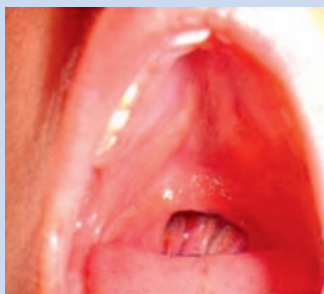

FIG. 53. *Absent uvula*. (Figure courtesy of Robert Shprintzen.)

Uvula, Broad

Definition: Increased width of the uvula (Fig. 54). *subjective*

Comments: This finding often accompanies a *Submucous cleft palate*, but this should be coded separately. A longitudinal groove indicating incomplete fusion of the two parts of the uvula may be present with a broadened uvula and has sometimes been called abortive cleft uvula.

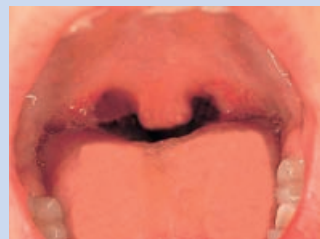


FIG. 54. *Broad uvula*. (Figure courtesy of Robert Shprintzen.)

Uvula, Cleft

Definition: Uvula separated into two parts most easily seen at the tip (Fig. 55). *objective*

Comments: *Submucous cleft palate* is a distinct entity.

Synonym: Bifid uvula

Uvula, bifid: see *Uvula, cleft*

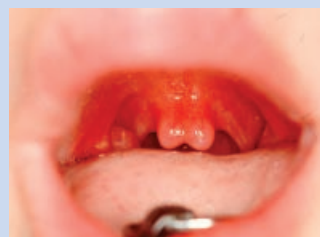

FIG. 55. *Cleft uvula*. Often called a bifid uvula, this feature is a component of a *submucous palate* but is common as an isolated feature.

Uvula, Long

Definition: Increased length of the uvula (Fig. 56). *subjective*

Comments: In clinical practice, the size of the uvula cannot be easily measured and is not static, since it depends on the position of

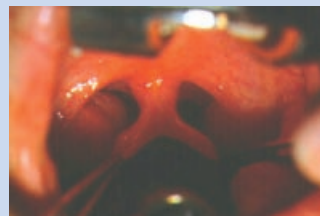

FIG. 56. *Long uvula*. Note the uvula is also cleft. (Figure courtesy of Robert Shprintzen.)

the soft palate, the base of the tongue, and the head. Therefore, judgment of change in length of the uvula depends heavily on the experience of the observer.

Uvula, Narrow

Definition: Decreased width of the uvula (Fig. 57). *subjective*

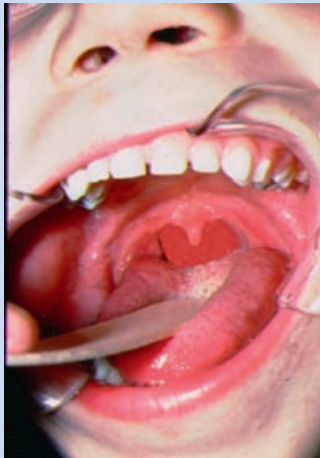

FIG. 57. *Narrow uvula.* (Figure courtesy of Robert Shprintzen.)

Uvula, Short

Definition: Decreased length of the uvula (Fig. 58). *subjective*

Comments: Objective measurement of the length of the uvula can be determined on a lateral cephalograms. However, in this series we are not relying on radiographs for assessment of findings. In clinical practice, the size of the uvula cannot be easily measured and is not static, since it depends on the position of the soft palate, the base of the tongue, and the head. Therefore, judgment of change in

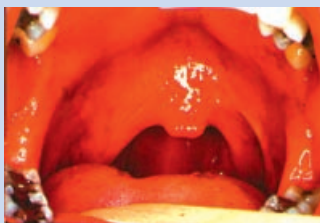


FIG. 58. *Short uvula.* (Figure courtesy of Robert Shprintzen.)

length of the uvula depends heavily on the experience of the observer.

Replaces term: Hypoplastic uvula

Uvula, hypoplastic: see *Uvula, short*

REFERENCES

- Aase J. 1990. Diagnostic dysmorphology. NY: Plenum Medical Book Co.
- Allanson JE, Biesecker LG, Carey JC, Hennekam RCM. 2009a. Elements of morphology: Introduction. *Am J Med Genet Part A* 149A:2–5.
- Allanson JE, Cunniff C, Hoyme HE, McGaughran J, Muenke M, Neri G. 2009b. Elements of morphology: Standard terminology for the head and face. *Am J Med Genet Part A* 149A:6–28.
- Astley SJ, Clarren SK. 2000. Diagnosing the full spectrum of fetal alcohol-exposed individuals: Introducing the 4-digit diagnostic code. *Alcohol* 35:400–410.
- Biesecker LG, Aase JM, Clericuzio C, Gurrieri F, Temple IK, Toriello H. 2009. Elements of morphology: Standard terminology for the hands and feet. *Am J Med Genet Part A* 149A:93–127.
- Cameron C, Widmer RP. 2003. Handbook of Pediatric Dentistry. 2nd edition. Edinburgh: Mosby.
- Farkas L. 1981. Anthropometry of the head and face in medicine. New York: Elsevier.
- Garn SM, Rohmann CG. 1966. Interaction of nutrition and genetics in the timing of tooth growth. *Pediatr Clin North Am* 13:353–363.
- Gorlin RG, Cohen MMC, Hennekam RC. 2001. Syndromes of the head and neck. Oxford: Oxford Press.
- Hall JG, Froster-Iskenius UG, Allanson JE, Gripp K, Slavotinek A. 2006. Handbook of Normal Physical Measurements. 2nd edition. Oxford: Oxford Medical, publishers.
- Hall BD, Graham JM Jr, Cassidy SB, Opitz JM. 2009. Elements of morphology: Standard terminology for the periorbital region. *Am J Med Genet Part A* 149A:29–39.
- Hennekam RCM, Cormier-Daire V, Hall J, Mehes K, Patton M, Stevenson R. 2009. Elements of morphology: Standard terminology for the nose and philtrum. *Am J Med Genet Part A* 149A:61–76.
- Hunter A, Frias J, Gillissen-Kaesbach G, Hughes H, Jones K, Wilson L. 2009. Elements of morphology: Standard terminology for the ear. *Am J Med Genet Part A* 149A:40–60.
- Kleigman RM, Behrman RE, Jenson HB, Stanton BF. 2007. Nelson's Textbook of Pediatrics. 18th edition. Philadelphia, PA: Saunders Elsevier. 47 p.
- Lunt RC, Law DB. 1974. A review of the chronology of eruption of deciduous teeth. *J Am Dent Assoc* 89:872–879.
- McDonald RE, Avery DA, Dean JA. 2004. Dentistry for the child and adolescent. St Louis: Mosby.
- Mok J, Suina RM. 1986. Natal teeth in native americans. *Am J Dis Child* 140:1214.
- Moyers RE. 1973. Handbook of Orthodontics for the Student and Practitioner. 3rd edition. Chicago: Yearbook.
- Moyers RE, van der Linden F, Riolo ML, McNamara JA. 1976. Standards of human occlusal development. Ann Arbor, MI: Center for Human Growth and Development.
- Standing S. 2005. Gray's anatomy: The anatomical basis of clinical practice. Edinburgh: Elsevier.