

Standard Terminology for Phenotypic Variations: The *Elements of Morphology* Project, Its Current Progress, and Future Directions

John C. Carey,^{1*} Judith E. Allanson,² Raoul C.M. Hennekam,³ and Leslie G. Biesecker⁴

¹Division of Medical Genetics, Department of Pediatrics, University of Utah, Salt Lake City, Utah; ²Department of Genetics, Children's Hospital of East Ontario, Ottawa, Canada; ³Department of Pediatrics, Academic Mental Center, UVA, Amsterdam, the Netherlands; ⁴National Human Genome Research Institute, National Institutes of Health, Bethesda, Maryland

For the Deep Phenotyping Special Issue

Received 1 November 2011; accepted revised manuscript 30 January 2012.

Published online 13 February 2012 in Wiley Online Library (www.wiley.com/humanmutation). DOI: 10.1002/humu.22053

ABSTRACT: In 2005, the authors of this article formed an international working group to develop standardized definitions and terms to describe the physical variations used in human phenotypic analyses. This project, which came to be known as the *Elements of Morphology*, resulted in six articles proposing consensus definitions for almost 400 phenotypic variations of the head and face; periorbital region; ear, nose, and philtrum; mouth and lips; and hands and feet. Every variation was accompanied by a representative figure depicting the feature. The articles were published in the January 2009 issue of the *American Journal of Medical Genetics Part A* and are available for free access on both the Journal's Web page and a National Institutes of Health-based site. The publication of the *Elements'* definitions has spawned an ongoing dialogue about the proposed terms to describe the phenotype. The working group considered the six articles as only the first step in the process, and four more articles on proposed terminology for the trunk, genital region, skin, and remainder of the limb terms are in preparation. The secondary outcome of the *Elements* project is the provision of a working methodology for the establishment of standardized terminology and definitions for phenotype analysis in general. *Hum Mutat* 33:781–786, 2012. © 2012 Wiley Periodicals, Inc.

KEY WORDS: phenotype; definitions; terminology; dysmorphology; nomenclature; minor anomalies

Introduction

Over the last two decades clinicians, scientists, the media, and the general public have witnessed and celebrated remarkable advances in the molecular basis of human disease. Gene discoveries in laboratories throughout the world in collaboration with medical geneticists have detected the underlying genetic cause of more than 2,000 different human conditions including, for example, cystic fibrosis and many congenital malformation syndromes. The inherent promises of these advances in knowledge of human genetics include improvements in diagnosis and the development of treatment and

prevention modalities for patients and their families. In order to discuss the role that gene mutations play in the pathogenesis of disease phenotypes, all of the stakeholders in this important process—clinicians, scientists, and patients and their families—need to have a common language to define the signs, symptoms, and manifestations of the various conditions, that is, standardized descriptions of human phenotypic variations. Using similar rationales, the International Standard Committee on Human Cytogenetic Nomenclature and the Nomenclature Working Group have established standardized definitions in cytogenetics and sequence variations, respectively [Carey, 2009].

The advances in molecular biology mentioned above occurred because of fruitful collaborations of medical geneticists and laboratory scientists. During the process of gene discovery, the researchers identified the need for a language to describe the phenotypes. Although a number of discussions among clinical geneticists had recognized this gap for years, that is, a lack of standardized terminology for phenotypic variations, it was not until 2004 that formal plans were set forth to convene a working group to propose definitions for the terms used in dysmorphology. In 2005, the authors of this article initiated the planning to establish an international group of clinicians experienced in clinical genetics and dysmorphology with the goal of standardizing nomenclature in clinical morphology and syndromology. Thirty-four individuals representing the three continents, North America, Europe, and Australia, were recruited to join six subgroups charged with proposing definitions [Allanson et al., 2009a]. Acknowledging this gap in knowledge—a lack of consensus and standardization of terms—the group formalized the goal of developing this needed nomenclature, established a methodology, and proposed the standardized definitions through a project that came to be known as the *Elements of Morphology*.

The aim of the present article is to summarize the methods used by this international working group, to highlight the results of the project, to document some of the outcomes of the project, and to articulate the future directions of the *Elements of Morphology* project.

Methods

The original plan of the leaders of the working group was to delineate definitions for all the terms in the London Dysmorphology Database (LDDDB, currently referred to as the Winter-Baraitser Dysmorphology Database; <http://www.lmddatabases.com>), a computerized resource for syndrome diagnosis [Merks et al., 2003]. The participants agreed that this list of 683 features was

*Correspondence to: John C. Carey, American Journal of Medical Genetics, 419 Wakara Way, Suite 213, Salt Lake City, UT 84108. E-mail: john.carey@hsc.utah.edu

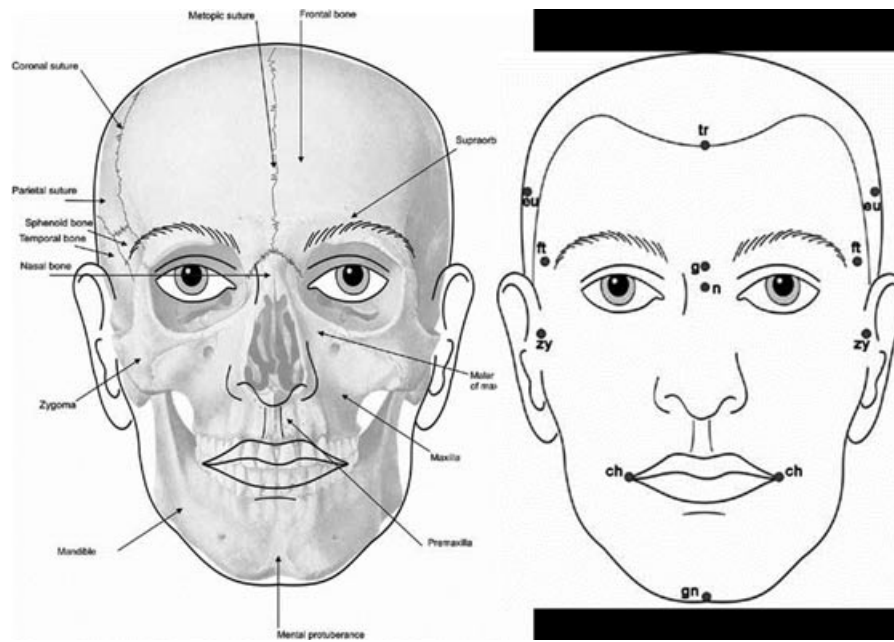


Figure 1. The drawings show the major anatomical landmarks of the face (left) and anthropological landmarks (right). (These drawings were taken from Figs. 1 and 2 in Allanson et al. [2009b] and are reproduced here with permission.)

the right place to initiate the process of definition of phenotypic variations; however, completion of this entire list of physical features was a daunting task. Therefore, the group chose to begin the project by narrowing the choice of terms to the craniofacial region and the hands and feet. The terms for these areas of the body were considered to be the most commonly used in the field to describe patients and delineate syndromes. This narrowed the list to just over 400 features in the LDDB.

Starting with this list, the 34 members were divided into the six working subgroups (see Table 1 in Allanson et al. [2009a]), which included the head and face; periorbital region; ear, nose, and philtrum; lips and mouth; and hands and feet. The group leaders then assigned about 10–15 features to each member of their respective subgroup, who were charged with defining each feature on their list and proposing a working definition for the entire group. The working group met initially in September 2005 at the National Institutes of Health (NIH) and again in November 2006 in Rome, Italy. The process of developing the consensus definitions was time consuming and stringent; it involved the drafting of the assigned definitions, attendance at the two meetings, hundreds of E-mails, perusal of over 400 figures, 2 years of revisions of the proposed definitions, and five Web-based conference calls by the four committee chairs who are authors of this article. The participants of each of the groups had input on all of the definitions in the other areas of the body. The committee chairs finalized the definitions and proposed them for review and discussion as the process proceeded to its 4-year conclusion and submission of the articles to the *American Journal of Medical Genetics*.

Results

At the first meeting, the group established a standard format and template to provide a definition and description to be accompanied by a figure for every variation. In addition, the authors contributed a series of definitions of the anatomy of that particular region of the body accompanied by drawings of important anatomical and

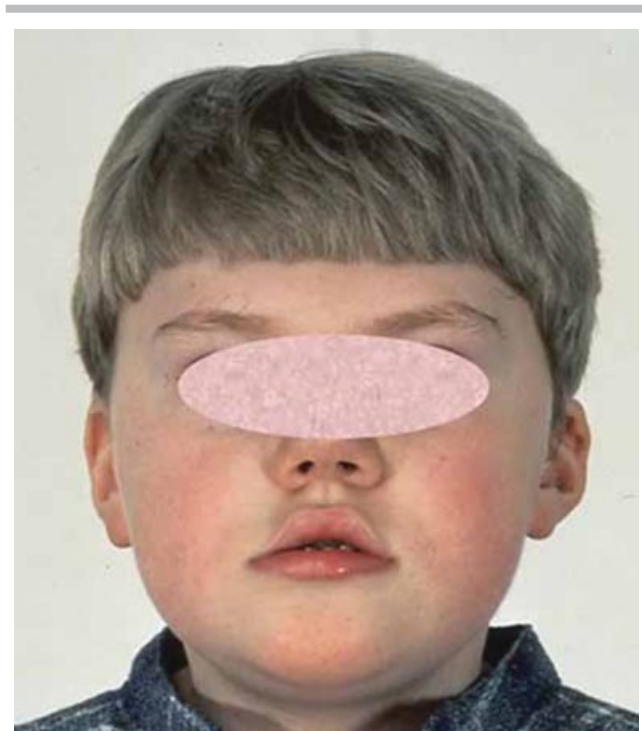

Figure 2. This photograph provides an example of a defined variation of the face, a *Broad Face*. See Box 1 for the standardized definition. (Republished from Allanson et al. [2009b] with permission.)

anthropological landmarks of the region (see Fig. 1 for an example of these drawings). Box 1 displays the standard terminology for a variation of the face shape, that is, *Broad face* (Fig. 2) as an example of the template. Each definition was stated in a dictionary format, refers to its accompanying figure, and, whenever possible,

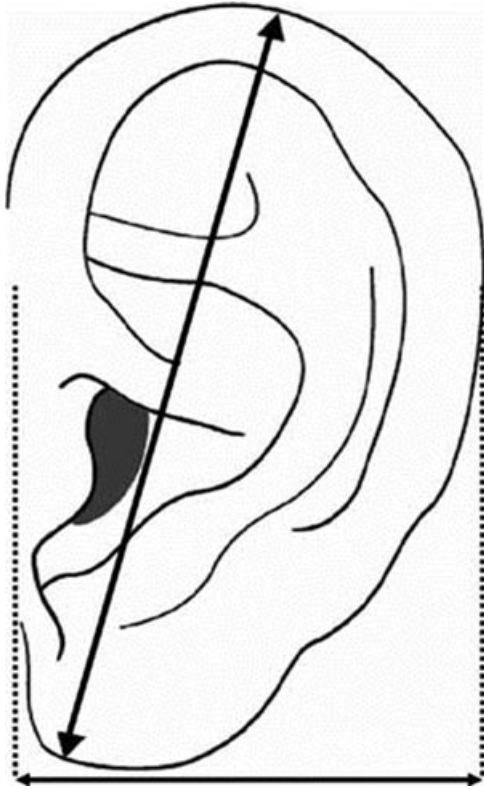


Figure 3. This drawing illustrates the method used to measure the ear length to determine a *Long Ear*. (Republished from Hunter et al. [2009b] with permission.)

provided both an *objective* statement (utilizing means and standard deviations of facial measurement when available) and a *subjective* definition. Comments on the individual features were appended to the definition when appropriate (see Box 1). The preferred term for the feature was always stated but when appropriate, acceptable synonyms were listed. Terms that were not considered the recommended one for the feature were listed in alphabetical order but then referred to the appropriate term (see Box 1, brows).

Box 1. Example of a Standardized Definition for Face Shape Variation

Face

Brows, prominent: See *Supraorbital ridges, prominent*
 Brows, underdeveloped: See *Supraorbital ridges, underdeveloped*

Face, Broad

Definition: *Objective:* Bizygomatic (upper face) and bigonial (lower face) width greater than 2 SD above the mean.
Subjective: An apparent increase in the width of the face
Comments: Objective measurement of upper facial width is made with spreading calipers. The tips of the calipers are passed over the zygomatic arches until maximum width is determined. Objective measurement of the lower face is made with spreading calipers, with the tips firmly pressed against the inferomedial surface of the angle of the mandible. Broad face is distinct from Round face.

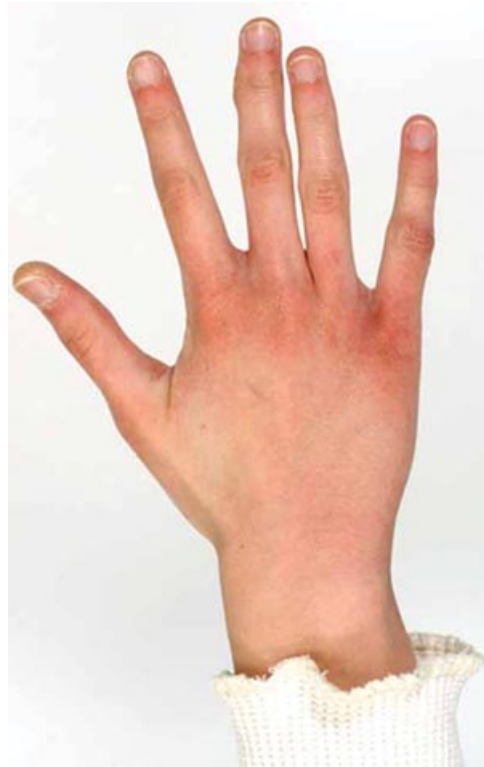

Figure 4. This photograph displays an example of a *Long Finger*, which can be determined by objective measurement. (Republished from Biesecker et al. [2009] with permission.)

During the process of consensus building, the working group made an effort to eliminate the following from the definitions: all pejorative terms (see Box 2 as an example), bundled terms (a term that represents two or more component findings, such as large nose [Hennekam et al., 2009]), and features requiring radiographs to define (e.g., hypodontia and oligodontia) [Carey et al., 2009]. Additionally, the group decided to exclude discussions of either the pathogenesis or the differential diagnosis of the included features. These latter aspects are clearly important but were not considered as the objective of this particular project [Allanson et al., 2009a].

Box 2. Examples of Removal of Pejorative Terms

Mouth, Downturned Corners of

Definition: Oral commissures positioned inferior to the midline labial fissure (Fig. 21 in Carey et al. [2009]) *subjective*
Comment: This finding should be assessed with the mouth closed, the lips in relaxed contact, and the face relaxed. The finding may be difficult to assess if the lower lip is enlarged.
Replaces: Carp mouth; Fish mouth (pejorative terms)

Needless to say, there was much discussion and often disagreement; however, a consensus was reached on the inclusion and definition of each feature. An example of disagreement is the entry of *Coarse Face*. Some members of the group considered coarse face a pejorative term for patients and families. It was also one of the exceptions to the rule of exclusion of bundle terms. However, the

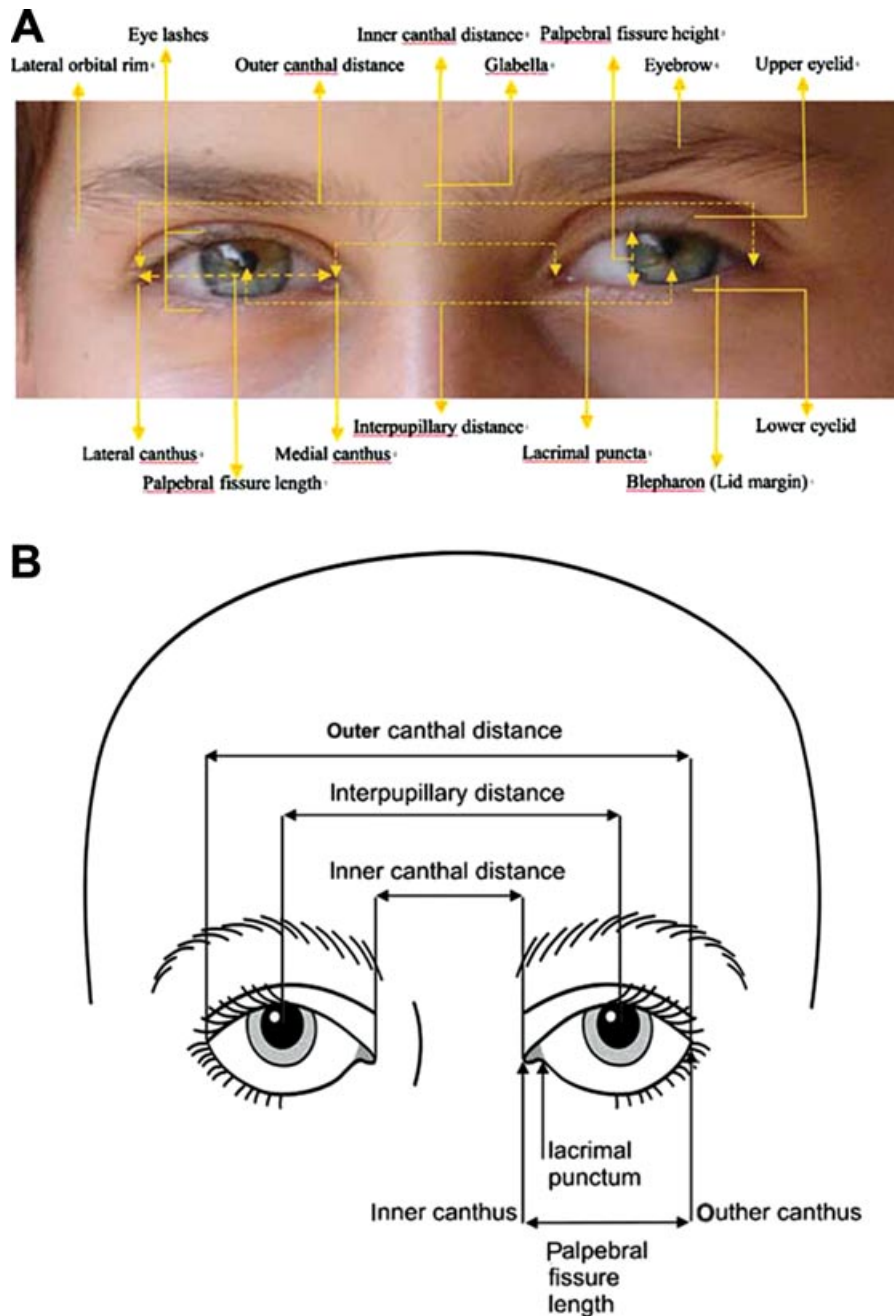


Figure 5. These figures demonstrate the anatomical landmarks of the periorbital region and the landmarks used to perform the various measurements of the eye. (Republished from Hall et al. [2009] with permission.)

consensus of the group was that it was still a “useful term” if used in its proper designation [Allanson et al., 2009b].

The working group recommended that, when available, the examiner or researcher should always use the *objective* version of the definition rather than the *subjective*. Figures 3–5 display figures that exemplify this point. Certainly, as is shown in Figures 3 and 4, it is better to measure an ear or hand with a ruler and plot the measurement on the published curves rather than refer to either structure as “long” [Biesecker et al., 2009; Hunter et al., 2009]. Figure 5 depicts the periorbital anatomy with the appropriate landmarks for measuring changes in eye spacing, a commonly used measurement by clinicians [Hall et al., 2009]. Figure 6 refers to another aspect of

many of the standardized definitions: When a gradation from one end of a spectrum to the other could be demonstrated by the figure, such a figure range was provided and explained [Hunter et al., 2009b].

Discussion

The six articles representing terms for these body regions were published in the January 2009 issue of the *American Journal of Medical Genetics Part A* [Allanson et al., 2009b; Biesecker et al., 2009; Carey et al., 2009; Hall et al., 2009; Hennekam et al., 2009; Hunter

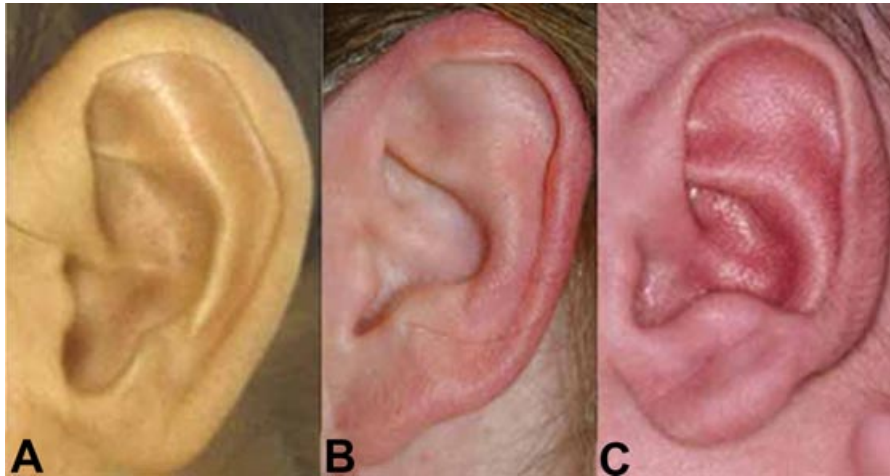


Figure 6. Photographs showing a continuum of alterations of the inferior crus of the antihelix. **A:** A thin crus, **B:** An average crus, and **C:** A thickened crus. (Republished from Hunter et al. [2009b] with permission.)

et al., 2009b]. The articles are available under the terms of the Creative Commons License, and readers who do not have a subscription to the *American Journal of Medical Genetics Part A* can see and download the articles. Access to the *Elements of Morphology* articles is provided on the Wiley online library Website for the *American Journal of Medical Genetics, Part A* (left-hand column, SPECIAL FEATURES). In addition, one of us (L.G.B.) created a National Human Genome Research Institute (NHGRI) Website that includes all of the individual features in all six articles available on the *Elements of Morphology* site (<http://elementsofmorphology.nih.gov/index.cgi>) [Biesecker and Carey, 2011]. In their editorial, Biesecker and Carey (2011), editors of the *American Journal of Medical Genetics*, have implemented the use of *Elements of Morphology* terminology in all manuscripts that use these related terms submitted to the *Journal*. In addition, the authors of this present article have contacted the editors of human and medical genetics journals requesting the inclusion of the standardized terms into manuscripts submitted to their journals and asking for the requirement of usage into the instructions for authors at their respective journals. The following sister journals concurred with this recommendation and have required the use of the *Elements* terminology in their respective journals: the *American Journal of Human Genetics*, *Clinical Genetics*, the *European Journal of Medical Genetics*, and *Clinical Dysmorphology*.

A number of international presentations and articles have followed the publication of this first portion of the *Elements of Morphology* project: Some of the authors of this article (J.C.C. and J.E.A.) presented an overview and examples of the implementation of the standardized definitions at an Invited Session of the 2009 American Society of Human Genetics meetings in Hawaii. Plans for such additional workshops are underway. In 2009, Kosaki orchestrated the translation of all of the definitions in the *Elements of Morphology* into Japanese and published these in the August 2010 issue of the *Japanese Journal of Pediatric Medicine* (www.tokyo-igakusha.co.jp) (Carey, 2010). This included the original figures, accompanied by the definitions translated into Japanese. Discussions to facilitate publication of the *Elements* into Polish are currently occurring, and plans to publish the *Elements of Morphology* in other languages are ongoing.

Since the publication of the *Elements* articles in 2009, numerous articles have appeared in the *American Journal of Medical Genetics* adding to, commenting on, or clarifying the definitions: Hunter

et al. (2009) applied the definitions in assessing the external ear in Cornelia de Lange syndrome. Wilson (2010) provided a “user’s guide” and commented on the application of the *Elements* terms. Möhrenschrager et al. (2010) questioned the definition of the term, central flaring of the eyebrow, and Hall and Hennekam (2010) responded to the query. In addition, Hunter (2010) proposed definitions of the incisura of the ear, which had not been included in the original *Elements*.

Moreover, one of the authors of this article (J.C.C.) has applied all of the definitions in the *Elements* into the development of a validated photographic and physical assessment instrument to be used in the National Children’s Study (NCS, www.nationalchildrensstudy.gov), a multistate NIH-funded national investigation designed to recruit thousands of US women early in pregnancy, track their outcomes, and examine the effects of environment and genetics on the health of children. The abstract describing this project and other related abstracts from the NCS will be published in an upcoming conference report in the *American Journal of Medical Genetics*.

The NHGRI-hosted Website also includes a comment function that allows users to suggest changes to the terminology. Lastly and notably, the Publishers of the *American Journal of Medical Genetics*, Wiley-Blackwell, have indicated to the authors that there have been over 21,000 downloads of the six terminology articles from the Journal’s Web pages as of October 2011 [Paalman, 2011, personal communication].

Future Directions

The publication of the six articles on the *Elements of Morphology* project is only the initial stage of the project. The leaders of the working group are planning to complete the remaining 380 findings in the LDDB that include the body segments of chest, trunk and abdomen, genitalia, the remainder of the limbs, and skin. The working draft of the terminology and definitions for the genital region has now been submitted to the authors (and other experts) and is currently under critical review before finalization and submission for publication. Eventually, we would hope that there would be a permanent committee with rotating membership, elected leadership, and funded activities. In acknowledgement of the goals of the *Elements of Morphology* project, the *American Journal of Medical Genetics* announced a Call for Articles for December 2011–January

2012 on growth charts on individuals with syndromes and on measurements of individual features.

The ultimate goal of the *Elements* project is to provide a framework for phenotypic definition and standardization of terms for all systems of the body and in all medical arenas. The authors strongly recommend that all articles in any publication that reports on human mutations include accurate and detailed phenotypic descriptions of the genotyped individuals. Without that, precise phenotype–genotype correlations cannot be established.

Acknowledgments

The authors acknowledge and appreciate the efforts and 4 years of hard work of all of the participants of the working group. They are grateful for the administrative expertise provided by Feliz Martinez in the preparation of this manuscript.

Disclosure Statement: The authors declare no conflict of interest.

References

- Allanson JE, Biesecker LG, Carey JC, Hennekam RCM. 2009a. Elements of morphology: introduction. *Am J Med Genet Part A* 149A:2–5.
- Allanson JE, Cunniff C, Hoyme HE, McGaughan J, Muenke M, Neri G. 2009b. Elements of morphology: standard of terminology for the head and face. *Am J Med Genet Part A* 149A:6–28.
- Biesecker LG, Aase JM, Clericuzio C, Gurrieri F, Temple IK, Toriello H. 2009. Elements of morphology: standard terminology for the hands and feet. *Am J Med Genet Part A* 149A:93–127.
- Biesecker LG, Carey JC. 2011. Implementing the elements of morphology in the American Journal of Medical Genetics. *Am J Med Genet Part A* 155A:969–971.
- Carey JC. 2009. Editorial comment: Editor’s foreword to a special issue “Elements of Morphology: Standard Terminology”. *Am J Med Genet Part A* 149A:1.
- Carey JC. 2010. Preface to Special Issue “Elements of Morphology: Standard Terminology” Japanese Version, *Japanese Journal of Pediatric Medicine* 42:1253–1254.
- Carey JC, Cohen MM Jr, Curry CJR, Devriendt K, Holmes LB, Verloes A. 2009. Elements of morphology: standard terminology for the lips, mouth, and oral region. *Am J Med Genet Part A* 149A:77–92.
- Hall BD, Graham Jr JM, Cassidy SB, Opitz JM. 2009. Elements of morphology: standard terminology for the periorbital region. *Am J Med Genet Part A* 149A:29–39.
- Hall BD, Hennekam RCM. 2010. Response to central flaring of eyebrow by Möhrenschrager et al. *Am J Med Genet Part A* 152A:1601.
- Hennekam RCM, Cormier-Daire V, Hall J, Méhes K, Patton M, Stevenson R. 2009. Elements of morphology: standard terminology for the nose and philtrum. *Am J Med Genet Part A* 149A:61–76.
- Hunter AG. 2010. The elements of morphology: ear—an initial approach for the incisura. *Am J Med Genet Part A* 152A:401–403.
- Hunter AG, Collins JS, Deardorff MA, Krantz ID. 2009a. Detailed assessment of the ear in Cornelia de Lange syndrome: comparison with a control sample using the new dysmorphology guidelines. *Am J Med Genet Part A* 149A:2181–2192.
- Hunter AG, Frias J, Gillessen-Kaesback G, Hughes H, Jone K, Wilson L. 2009b. Elements of morphology: standard terminology for the ear. *Am J Med Genet Part A* 149A:40–60.
- Merks JHM, van Karnebeek CDM, Caron HN, Hennekam RCM. 2003. Phenotypic abnormalities: terminology and classification. *Am J Med Genet Part A* 123A:211–230.
- Möhrenschrager M, Ring J, Lauener R. 2010. Central flaring of eyebrow. *Am J Med Genet Part A* 152A:1600.
- Wilson GN. 2010. A user’s guide to the elements of standard morphologic terminology: analysis and database. *Am J Med Genet Part A* 152A:1627–1629.